

A clinical study of outcome of two different methods of meatoplasty following modified radical mastoidectomy



Surbhi¹, Shaheen Zafar², Rohit Kumar³

^{1,2}Senior Resident, ³Post Graduate Resident, Department of ENT, Patna Medical College and Hospital, Patna, Bihar, India

Submission: 23-02-2022

Revision: 27-05-2022

Publication: 01-07-2022

ABSTRACT

Background: Meatoplasty usually is the final step of a canal wall down mastoidectomy. It provides sufficient enlargement of the external auditory meatus which leaves the patient with a smaller mastoid recess that could readily be cleaned and examined without anatomical restriction. **Aims and Objectives:** The aims of this study were to study the outcome of two different methods of meatoplasty following modified radical mastoidectomy. **Materials and Methods:** This is a prospective study done for 2 years from January 2020 to December 2021 on 50 patients of chronic otitis media unsafe type, where modified radical mastoidectomy was done followed by meatoplasty. **Results:** The result in both the groups is comparable up until the meatus remains wide and large which could facilitate cavity examination, aeration, debridement, and drainage. **Conclusion:** Outcome was favorable in both the groups and complications related to the meatoplasty technique was also comparable.

Keywords: Cholesteatoma; Mastoidectomy; Otitis media

Access this article online

Website:

<http://nepjol.info/index.php/AJMS>

DOI:10.3126/ajms.v13i7.43350

E-ISSN: 2091-0576

P-ISSN: 2467-9100

Copyright (c) 2022 Asian Journal of Medical Sciences



This work is licensed under a Creative Commons Attribution-NonCommercial 4.0 International License.

INTRODUCTION

Modified radical mastoidectomy is done to remove cholesteatoma in unsafe types of chronic otitis media. It involves exteriorizing the disease from middle ear, attic, and mastoid cavity with posterior canal and lateral attic wall removal. Extensive disease demands removal of posterior canal wall removal with removal of as much diseased mucosa possible into the external auditory canal. It also addresses the disease in the hidden areas of the ear in cases of poorly pneumatized mastoid cavity and cholesteatoma leading to complications. Fistula in the lateral semicircular canal and dehiscence of the posterior wall highly call for modified radical mastoidectomy. Meatoplasty is done to enlarge the opening of external canal in modified radical mastoidectomy. The purpose of mastoidectomy is to facilitate ventilation of mastoid cavity as well as it helps

visualization and debridement of mastoid cavity. There are different techniques of meatoplasty done by different surgeons all focused on the purpose of widening the external canal opening.

Aims and objectives

The aims of this study were to study the outcome of two different methods of meatoplasty following modified radical mastoidectomy.

MATERIALS AND METHODS

This study was done for 2 years from January 2020 to December 2021 in the Department of ENT, Patna Medical College and Hospital. The patients were sorted based on clinical findings and investigations. The patients of chronic

Address for Correspondence:

Dr. Shaheen Zafar, Senior Resident, Department of ENT, Patna Medical College and Hospital, Patna - 800 004, Bihar, India.

Mobile: +91-9955901433. **E-mail:** zafaronline1@yahoo.co.in

otitis media having suspicion of cholesteatoma were duly examined by otoscopy followed by dry mopping and microscopic examination of the ear, where it was needed. Inclusion and exclusion criteria were set and patients following inclusion and exclusion criteria were selected. Consent was taken from all the patients for participation in the study. The study was pre-approved by the Institutional Ethics Committee for the final permission.

Inclusion criteria

The inclusion criteria were included in the study:

- Age group between 12 and 24 years
- Cholesteatoma requiring modified radical mastoidectomy
- Chronically discharging ear
- No intracranial and extracranial complications
- Consent taken for the study on them
- Complying to regular follow-up
- Psychologically sound

Exclusion criteria

The inclusion criteria were excluded from the study:

- Not giving consent for the study on them
- Complicated chronic otitis media
- Comorbid conditions

Fifty patients who were following the inclusion and exclusion criteria, a consent form was duly signed by them after explaining the protocol of the study. Patients were examined properly and high-resolution computed tomographic scan was done and finer sections of 2mm and 4mm were taken out which were studied and surgery was accordingly planned. Pure tone audiometry was done to note down the pre-operative hearing status of patients.

Patients were then randomly divided into two groups of 25 patients each.

Group 1: Offered modified radical mastoidectomy and single cut meatoplasty

Group 2: Underwent radical mastoidectomy and conchomeatoplasty with cartilage excision

Surgical techniques

Postauricular approach was taken in all the patients. Modified radical mastoidectomy was done in both the groups, where complete mastoid air cells were removed followed by middle ear examination and disease removal followed by reconstruction where needed. In the end of the surgery, meatoplasty was done.

Single cut meatoplasty

- Single incision is taken to incise the conchal cartilage, subcutaneous tissue, and the skin from medial to the lateral.

- Incise the skin inferiorly from intertragic notch up until the lateral border of the concha is reached.
- Two 2-0 Vicryl sutures were taken just lateral to the periosteum to secure the posterior cartilaginous semi-ring to the posterior edge of our postauricular incision.
- The entire cartilaginous ring at its posterior part including the concha is released and moved it backward, thereby to create a larger ear canal (Figure 1).

Conchomeatoplasty with cartilage excision

- A flap of conchal skin is raised just above the perichondrial layer, which was posterosuperiorly based.
- The skin of the posterior cartilaginous ear canal is then dissected off underlying cartilage and soft tissue. This canal skin flap is released superiorly to make an inferiorly based flap out of ear canal skin.
- The conchal cartilage is excised in a semilunar thin stripe, and underlying soft tissue is either excised or incised to further create a wide meatus.
- The conchal skin flap is rotated medially and sutured with absorbable suture to the soft tissue on the surface of the pinna, and the flap of posterior canal skin is rotated almost 90° which was sutured to the skin edge of the inferior conchal cut.

Patients were followed-up for 1 year. Complications following two different types of meatoplasty was analyzed. Success of meatoplasty was assessed by width of meatoplasty at the end of one ear on follow-up examination.

Statistical analysis

Statistical analysis was done using SPSS statistics version 24 for windows. All statistical tests were two tailed and $P < 0.05$ was considered significant. Categorical variables were compared using Chi-square test while continuous variables by unpaired t-test.

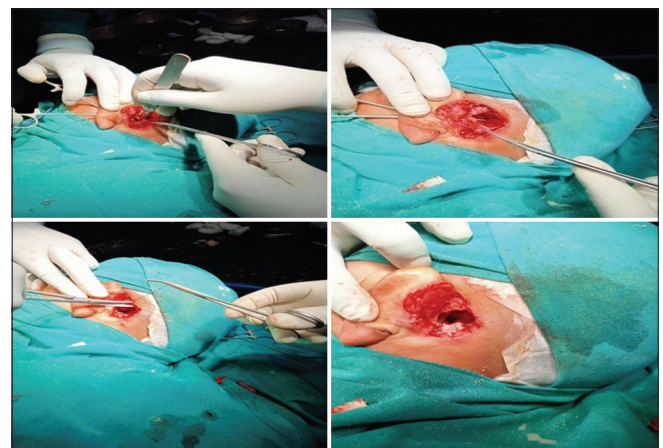


Figure 1: Different steps of single cut meatoplasty

RESULTS

Out of 50 patients 30(60%) were male and 20 (40%) females. Mean age is 17.78 and variance 13.56. Standard deviation is 3.6 where N is 50. Confidence interval being 95%,1.960 with margin of error $17.78 \pm 1.02 (\pm 5.74\%)$ Charts 1 and 2. Patients were followed up to 1 year and success of the meatoplasty was calculated by the size of meatoplasty at the end of 1 year, Table1. None of the patients showed perichondritis or canal stenosis. Three patients in Group 2 reported with granulation on the meatal incision which was later cured by chemical cautery using 20% silver nitrate

Table 1: Number of patients with meatal size after surgery

	Wide >10 mm	Adequate 10–8 mm	Narrow <8 mm
Single cut meatoplasty	18	7	0
Cartilage excision meatoplasty	20	5	0

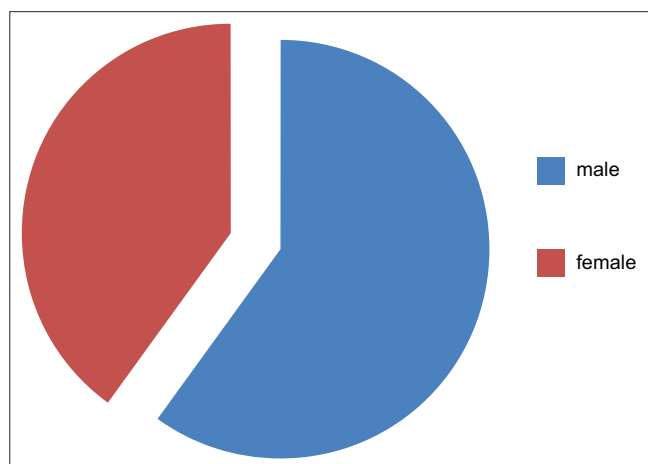


Chart 1: Sex distribution

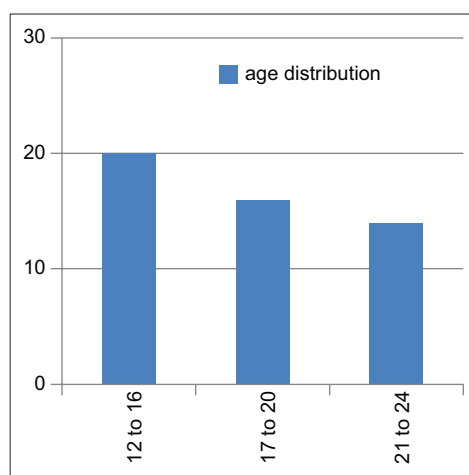


Chart 2: Age distribution

solution. One patient of Group 2 showed cosmetic defect of the pinna due to large sized meatoplasty. Rest no other factor showed any association with failure of meatoplasty leading to failure of the surgery. P value was calculated using Chi-square which was found to be < 0.05 , and therefore, the study can be accepted. The two tailed P value is 0.0009 with chi-square test value is 20.841 and 5 degrees of freedom. By conventional criteria, this difference is considered to be extremely statistically significant.

DISCUSSION

Anatomic changes in external auditory canal can expose ear to diseases due to differential aeration due to narrow external meatus. Hunsaker performed lateral conchomeatoplasty on 50 patients which showed improvement.¹ Mirck performed M-Meatoplasty of the external auditory canal in cases of chronic otitis external or in collapsed concha in plugging of wax. This can also be done in combination with tympano-mastoidectomy or modified radical mastoidectomy.² In advanced cases of chronic otitis media or other types of ear disease, an otologist may decide to perform canal wall down (CWD) mastoidectomy surgery. At the end of a CWD mastoidectomy procedure, the external auditory meatus must be widened to provide a dry, self-cleaning ear, and to allow for in-office surveillance.³ A large sized meatoplasty supports rapid epithelialization and exteriorization of the mastoid cavity size. Inability to perform an adequate meatoplasty may lead to cholesteatoma formation, chronic secretion, and post-operative canal stenosis.⁴ A small meatus after CWD mastoidectomy can cause a permanent problem, and unacceptable results are frequently encountered.⁵ Eisenman et al., succeeded in getting a larger meatal area without the need to further extend the posterior conchomeatoplasty, thus avoiding potential cosmetic deformity.⁶ The method used by Wormald and Van Hasselt the mean largest diameter of the meatus was 10.1 mm and the mean smallest diameter was 8.3 mm; these diameters are comparable with other meatoplasty.⁷ Hovis et al., found that one-cut meatoplasty supports a stable and healthy, open cavity with functional results that are comparable favorably to other series evaluating modified radical mastoidectomy with traditional meatoplasty.⁸

Our study was done to compare the two different methods of meatoplasty. First involving single cut in the conchal cartilage and other involving removal of a piece of crescent shaped cartilage. Both the groups showed comparable result with minimal complications following cartilage excision and cartilage incision.

Limitations of the study

Our study covers only young patients.

CONCLUSION

This study was to see the outcome of two different methods of meatoplasty. One involving single cut incision in the cartilage and other involving removal of a crescent shaped cartilage piece. The aim in both the types was to widen the meatus aiding aeration of mastoid cavity, cleaning and visualization of cavity. The result in both the groups is comparable up until the meatus remains wide and large which could facilitate cavity examination, aeration, debridement, and drainage.

ACKNOWLEDGMENT

We acknowledge our HOD, Dr Vineet Sinha sir for guiding in this study and all the patients who participated.

REFERENCES

1. Hunsaker DH. Conchomeatoplasty for chronic otitis externa. Arch Otolaryngol Head Neck Surg. 1988;114(4):395-398. <https://doi.org/10.1001/archotol.1988.01860160039017>
2. Mirck PG. The M-Meatoplasty of the external auditory canal. Laryngoscope. 1996;106(3):367-369. <https://doi.org/10.1097/00005537-199603000-00024>
3. Paparella MM and Kurkjian JM. Surgical treatment for chronic stenosing external otitis (Including finding of unusual canal tumor). Laryngoscope. 1966;76(2):232-245. <https://doi.org/10.1288/00005537-196602000-00004>
4. Soliman T, A Fatt-Hi M and Kadir A. A simplified technique for the management of acquired stenosis of the external auditory canal. J Laryngol Otol. 1980;94(5):549-552. <https://doi.org/10.1017/S0022215100089234>
5. Choi IJ, Song JJ, Jang JH and Chang SO. A novel meatoplasty method in canal wall down tympanomastoidectomy: A perichondrial posterior fixation technique. ClinExpOtorhinolaryngol. 2009;2(4):164-168. <https://doi.org/10.3342/ceo.2009.2.4.164>
6. Eisenman DJ and Parisier SC. Meatoplasty: The cartilage of the floor of the ear canal. Laryngoscope. 1999;109(5):840-842. <https://doi.org/10.1097/00005537-199905000-00031>
7. Wormald PJ and Van Hasselt CA. A technique of mastoidectomy and meatoplasty that minimizes factors associated with a discharging mastoid cavity. Laryngoscope. 1999;109(3):478-482. <https://doi.org/10.1097/00005537-199903000-00025>
8. Hovis KL, Carlson ML, Sweeney AD and Haynes DS. The one-cut meatoplasty: Novel surgical technique and outcomes. Am J Otolaryngol. 2015;36(2):130-135. <https://doi.org/10.1016/j.amjoto.2014.10.002>

Authors Contribution:

S- Concept and design of the study, prepared first draft of manuscript, interpreted the results; **SZ-** Reviewed the literature, interpreted the results; **RK-** Reviewed the literature and manuscript preparation, statistical analysis and interpretation

Work attributed to:

Patna Medical College and Hospital, Patna - 800 004, Bihar, India

Orcid ID:

Dr. Surbhi - <https://orcid.org/0000-0002-3373-6917>

Dr. ShaheenZafar - <https://orcid.org/0000-0002-3732-4610>

Dr. Rohit Kumar - <https://orcid.org/0000-0003-4952-7682>

Source of Funding: None, **Conflicts of Interest:** None.