

Study of Laparoscopic Inguinal Hernia Repair Using an Anatomically Contoured 3D Mesh



Nilesh Mangam¹, Dhaval Gosaliya²

¹Associate Professor, Department of General Surgery, Government Medical College, Chandrapur, Maharashtra

²Senior Resident, Department of Urology, Bombay Hospital, Mumbai

Submission: 03-04-2021

Revision: 21-07-2021

Publication: 01-08-2021

ABSTRACT

Background: Laparoscopic inguinal hernia surgery frequently is performed with mechanical fixation of polypropylene mesh. This mechanical fixation, though is necessary to prevent mesh migration, may be associated with pain syndromes and buckling. Recently an anatomically contoured 3D mesh (developed by Dr. Philippe Pajotin) has been introduced which is made up of monofilament polypropylene and resembles normal inguinal area curvature. **Aims and Objective:** This study was conducted to know whether elimination of tacking the 3D mesh during Total extraperitoneal approach (TEP) inguinal hernia repair results in decreased postoperative pain without increasing the incidence of hernia recurrence. **Materials and Methods:** This was a prospective interventional study in which 63 patients with clinical diagnosis of inguinal hernia were included on the basis of a predefined inclusion and exclusion criteria. All selected patients underwent laparoscopic TEP inguinal hernia repair using anatomically contoured 3D mesh. Patients were assessed for postoperative pain (using visual analogue scale) during their stay in the hospital as well as in the follow up period. **Results:** In this study of Laparoscopic inguinal hernia surgery using anatomically contoured 3D mesh of 63 male patients the most common affected age group was found to be 41-50 years (25.3%) with a mean age of 47.12 years \pm 13.01. Most common inguinal hernia was of indirect type (50.7%) and was seen on right side (52.3%). Mean operative time was 113.57 \pm 29.04 minutes in unilateral and 170.6 \pm 5.85 minutes in bilateral inguinal hernias. Postoperative mean VAS score (12 hrs) was found to be 3.46 \pm 1.51. During follow up at 1 week, 1 month and 3 months mean VAS scores were found to be 0.46 \pm 0.50, 0.14 \pm 0.35 and 0.01 \pm 0.12 respectively. Common complications included seroma (12.6%), pneumoscrotum (7.9%) and peritoneal breach (6.3%). None of the patients developed recurrence during follow up period. **Conclusion:** An anatomically contoured mesh for laparoscopic preperitoneal hernia repair usually requires no fixation and has minimal complications. It is associated with excellent recovery and marked reduction in pain.

Keywords: Inguinal Hernia; Laparoscopic Surgery; Anatomically Contoured 3D Mesh; VAS Scores; Outcome

INTRODUCTION

Inguinal hernia repair is one of the most common surgical procedures performed worldwide. Inguinal hernioplasty has undergone a gradual evolution over the last 100 years. In the beginning, surgeons like Edoardo Bassini, William Halsted, and Chester McVay championed new understandings of hernia anatomy and fresh approaches to dissection and repair of the inguinal floor.¹

In the 1970s surgeons began to incorporate prosthetic materials into their repairs to eliminate tension and to decrease recurrence. Later Nyhus, Stoppa, and Wantz further changed the direction of inguinal hernioplasty by applying prostheses to the posterior wall of the groin.² The evolution reached its current level in 1990 shortly after the introduction of laparoscopic cholecystectomy, when the laparoscopic approach to inguinal hernia repair was introduced.

Access this article online

Website:

<http://nepjol.info/index.php/AJMS>

DOI: 10.3126/ajms.v12i8.36267

E-ISSN: 2091-0576

P-ISSN: 2467-9100

Copyright (c) 2021 Asian Journal of Medical Sciences



This work is licensed under a Creative Commons Attribution-NonCommercial 4.0 International License.

Address for Correspondence:

Dr Nilesh Mangam, Ward No 12, Sindhi colony, Post Taluka, MUL, District- Chandrapur, Pin: 441224. **Mobile:** +91-9922432529.

E-mail: nileshmangam3@gmail.com

Since first reported by Ger et al., who first describes management of inguinal hernia by closure of neck of hernial sac, laparoscopic hernia repair also has evolved considerably and many surgeons have later come up with different techniques.³ The laparoscopic inguinal surgery is becoming more popular and acceptable since last 2-3 decades because of its low morbidity and fast recovery. Moreover, laparoscopic inguinal repairs have been found to be associated with comparatively less complications and better outcomes as compared to open surgeries.⁴ The problems associated with laparoscopic hernia repairs include seroma or hematoma formation (seen in up to 20% of the patients undergoing laparoscopic hernia repair), postoperative pain, Neuralgias, testicular pain, mesh infection and recurrence of hernia.⁵ The recurrence of inguinal hernia after laparoscopic surgery may be due to inadequate reduction of hernial sac, improper placement of mesh and not ensuring adequate hemostasis before placing the mesh. Adequate training and proper technique may reduce the chances of recurrences after laparoscopic hernia repair.⁶

Usher was first to report repair of inguinal hernias with mesh in 1958.⁷ Since then the use of mesh for hernia surgeries has become a routine and the technique and types of meshes have also been evolved considerable.⁸ The use of mesh has distinct advantage of having less pain, more rapid recovery, and low recurrence rates as compared to surgeries in which mesh is not used. According to some studies the recurrence rates in hernia surgeries without mesh reaches up to 20% while the recurrence rates in hernia repair using mesh is less than 1%.⁹

Recently an anatomically contoured 3D mesh developed by Dr. Philippe Pajotin has been introduced which is made up of monofilament polypropylene and resembles normal inguinal area curvature.¹⁰ It has memory in the individual fibers of the polypropylene which results in even and quick placement of mesh. The mark on the medial aspect allows the surgeon to correctly orient the mesh covering the entire myopectineal orifice. The unique shape of 3D mesh is designed to conform to the anatomy and minimizes buckling that may be seen with ordinary flat mesh, which reduces the need for mechanical fixation.¹¹

The purpose of this study was to determine whether elimination of tacking the 3D mesh during TEP inguinal hernia repair results in decreased postoperative pain without increasing the incidence of hernia recurrence.

MATERIALS AND METHODS

This was a prospective interventional study in which 63 patients with clinical diagnosis of inguinal hernia

(direct/indirect/bilateral) admitted at tertiary care center were included depending upon a predefined inclusion and exclusion criteria. The duration of study was 2 years. All selected patients underwent laparoscopic TEP inguinal hernia repair using 3D contoured anatomical mesh. The records of the patient were collected through a prescribed proforma wherein it contained history, clinical findings, investigations and surgical procedure done. All the patients were admitted and a detailed history and clinical examination was carried out as per written proforma. After taking consent for the operative procedure, the patient was investigated thoroughly. Once the patient was deemed fit for surgery, informed consent was taken in written for the same. Apart from the routine investigations, pre-operative evaluation of patients for laparoscopic TEP repair included Ultrasound of abdomen and pelvis, mainly to rule out prostate enlargement in above 50 years of age. A dose of prophylactic antibiotic (Inj. amoxiclav 1.2gm) was given 30 minutes before surgery. Patients were assessed for postoperative pain during their stay in the hospital as well as in the follow up period. Pain assessment was done by VAS (visual analogue scale) during hospital stay and in postoperative follow up period. (12 hours, 24 hours, 1 week, 1 month, 3 months).

Inclusion criteria

1. Patients aged 18 years and above giving written valid consent.
2. Patients diagnosed as having uncomplicated reducible unilateral/bilateral and direct/indirect inguinal hernia.
3. Patients medically fit to undergo the procedure.
4. Patients who are ready for regular follow up.

Exclusion criteria

1. Patient under the age of 18 years are excluded.
2. Recurrent and complicated inguinal hernia.
3. Uncorrected coagulopathy, morbid obesity, suspected intra-abdominal and pelvic malignancy.
4. Previous abdominal surgery

The Technique Of Laparoscopic Repair Of Direct And Indirect Inguinal Hernia By Total Extra Peritoneal Hernioplasty (TEP) Using 3d Contoured Anatomical Mesh:

The patient was placed in a supine position with both arms tucked at the side, and a single video monitor was placed at the foot end of the operating table. Laparoscopic TEP hernia repair was performed under general anesthesia. After proper skin preparation A 12 mm sub umbilical incision (arciform incision) extending up to linea Alba was made. The anterior rectus sheath was incised transversely and the entire rectus muscle was retracted to anterolateral side to enter the space between the muscle and posterior rectus sheath. A purse string suture was given with thick

suture material of silk 2-0 around the cannula with a wet gauge or Vaseline gauge plugged between the skin and the cannula to prevent the leakage of gas. Extra peritoneal space creation was done with the blunt introduction of 10 mm laparoscope (0 degree). Zero-degree scope was used for initial creation of space and then changed to 30-degree scope for rest of the dissection. The blunt dissection beyond midline was performed by dividing the ventral lamina of the transversalis fascia. If a direct hernia was present, it was reduced with gentle traction on the peritoneal attachments within the defect. After dissection of the direct floor, the femoral area was examined. In cases of indirect hernia, the edge of the peritoneum was grasped with an atraumatic grasper and lifted off the testicular vessels, the sac was dissected of the cord and hernia was reduced.

After creating adequate pre-peritoneal dissection, a medium / large size 3D mesh is deployed through 10 mm size 3D mesh is deployed through 10 mm port and placed in pre-peritoneal space in anatomically correct position to completely cover the defect. Size of the mesh was decided intraoperatively according to the defect. Once the mesh is fully in the extra peritoneal compartment, it is repositioned using two graspers. Any folding or wrinkling of the mesh was avoided. Finally, the CO2 was released slowly by opening the side channel of a 5 mm port to empty the extraperitoneal space and the scrotum. This was done under vision to see that mesh is properly placed. The ports were removed under vision after lifting the anterior abdominal wall. The rectus sheath was approximated and the trocar wounds were closed with mattress sutures. The sheath of 10 mm port was closed with vicryl 2-0 suture. Skin cuts were closed with ethylone 3-0.

RESULTS

The study comprised of 63 male patients who have undergone laparoscopic TEP repair using an anatomically contoured 3D mesh. The analysis of age groups of the patients showed that the most common age group was 41-50 years (25.3%) followed by 51-60 years (23.8%). Least common affected age group was above 70 years (Table 1).

The analysis of the side of inguinal hernia showed that in 33 patients (52.3%) inguinal hernia was on right side while in 21 patients (33.3%) it was on left side. Bilateral Inguinal hernia was seen in 9 (14.2%) patients (Figure 1).

The analysis of type of inguinal hernia showed that the most common type of hernia was indirect hernia (50.7%) followed by direct hernia (34.9%). In 9 (14.2%) patients a combination of direct and indirect hernia (pantaloon hernia) was seen (Figure 2).

The time required for surgery was noted in all the cases. In majority of the cases (47.6%) the time required for completion of surgery was 81-100 minutes followed by 101-120 minutes (23.8%). Mean time for surgery in unilateral and bilateral hernia was found to be 113.57 ± 29.04 and 170.6 ± 5.85 respectively (Table 2).

There was a considerable reduction of pain in operated cases over the period of 24-48 hours. The analysis of VAS score showed that mean VAS score at 12 and 24 hours was 3.46 and 1.65 respectively. During follow up there

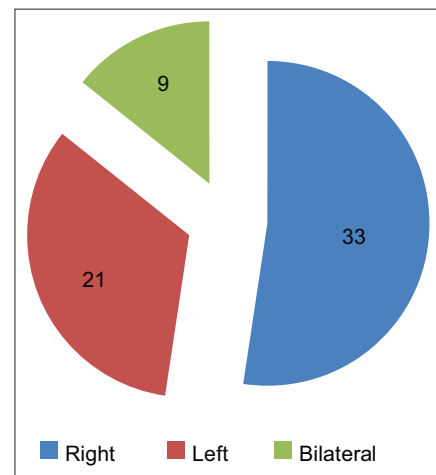


Figure 1: Side of hernia in studied cases

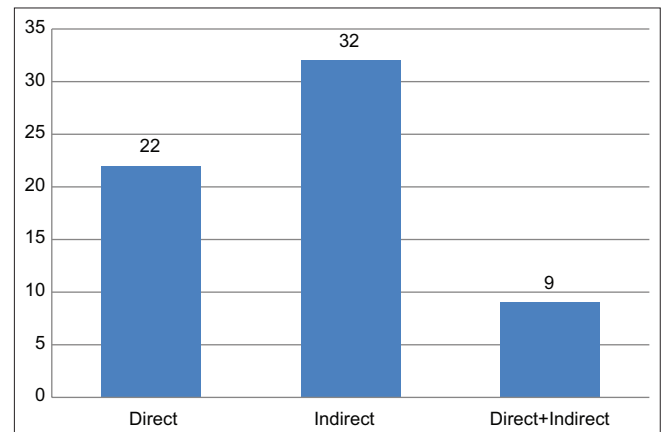


Figure 2: Distribution of patients according to type of hernia

Table 1: Distribution of patients according to age group

Age in years	Number of patients	Percentage (%)
21-30	10	15.87%
31-40	10	15.87%
41-50	16	25.40%
51-60	15	23.81%
61-70	10	15.87%
71-80	2	3.17%
Total	63	100%

Mean Age = Mean +SD 47.12 ± 13.01

was significant reduction in VAS scores and after 1 week postoperatively the mean VAS score was found to be 0.46 (Table 3).

Twelve hours after surgery 4 (6.3%) patients had severe pain while 23 (36.5%) and 36 (57.14%) patients had moderate and mild pain respectively. 24 hours postoperatively there was a significant reduction in pain and no patient had severe pain. During 1week, 1 month and 3 months follow up 34 (53.9%), 54 (85.7%) and 62 (98.4%) had no pain while 29 (46%), 9 (14.2%) and 1 (1.5%) had mild pain (Figure 3).

The analysis of patients for complications showed that the most common complication seen in studied cases was found to be seroma (12.0 %) followed by pneumoscrotum (7.9%) and peritoneal breach (6.3%). The other less common complications in postoperative period were subcutaneous emphysema (3.1%), genital edema (3.1%) and urinary retention (1.5%) (Table 4).

In majority of the patients (66.6%) time required for ambulation was less than 5 hours. 18 (28.5%) patients required 6-8 hours for ambulation. 9-11 and more than

11 hours was required in 2 (3.1%) and 1 (1.5%) patients respectively. Mean time required for post-operative ambulation was 5.04 ± 1.83 hours (Table 5).

Postoperatively majority of the patients (96.8%) could be discharged within 24 hours while 2 (3.1%) were hospitalized for more than 24 hours in view of pain (Figure 4).

There was no case of recurrence in any of the patients during follow up period of 3 months.

DISCUSSION

Sixty-three patients with clinical diagnosis of inguinal hernia underwent laparoscopic TEP repair using an anatomically contoured 3D mesh. No spiral tackers, sutures or clips were used to fix the mesh. Patients were assessed during the postoperative hospital stay and during follow up period. The minimum follow up period of the patients was 6 months. The mean operative time for unilateral and bilateral inguinal hernia was found to be 113.57 minutes and

Table 2: Mean Time for surgery required in patients

Operative Time In Minutes	Number Of Patients	Percentage
81-100	30	47.6
101-120	15	23.8
121-140	7	11.1
141-160	2	3.1
160-180	9	14.2

Mean +/- SD: Unilateral Hernia- 113.57 ± 29.04
Bilateral Hernia - 170.6 ± 5.85

Table 3: Mean VAS scores during postoperative period and during follow up

Post-Operative Time	Mean Vas Score	SD
12 Hours	3.46	1.51
24 Hours	1.65	1.00
1 Week	0.46	0.50
1 Month	0.14	0.35
3 Months	0.01	0.12

Table 4: Postoperative Complications in studied cases

Complications	No. of patients	Percentage
Peritoneal breach	4	6.3%
Pneumoscrotum	5	7.9%
Urinary retention	1	1.5%
Subcutaneous emphysema	2	3.1%
Genital edema	2	3.1%
Seroma	8	12.6%
Total	22	34.92%

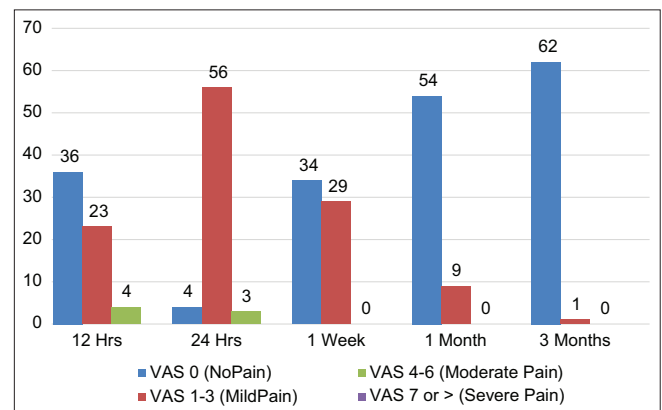


Figure 3: Severity of Pain during postoperative period and during follow up

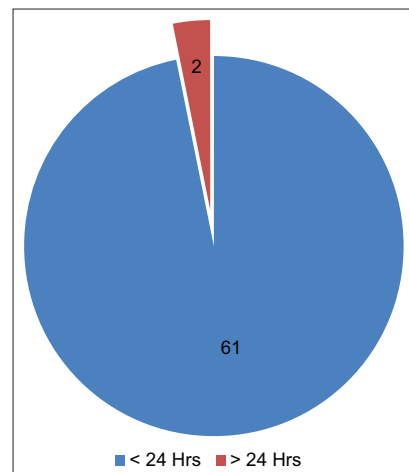


Figure 4: Post-operative hospital stay in studied cases

Table 5: Time required for ambulation in the studied cases

Time in hours	No. of patients	Percentage
3-5	42	66.6%
6-8	18	28.5%
9-11	2	3.1%
>11	1	1.5%
Total	63	100 %

170.6 minutes respectively. Similar results were reported by Yassar Hamaza et al.¹² The other authors like K. McCormack et al.,¹³ reported a relatively less time required for surgery (46 minutes). The time required for laparoscopic surgeries depends upon training and experience of operating surgeon and as the operating surgeons gain experience the operative time usually decrease.

Pain is a difficult parameter to assess. Individual variation, personal expectations and social implications all affect pain perception and expression. Postoperative pain score was assessed by visual analogue scale. Postoperative pain was assessed at 12 hours, 24 hours, 1 week, 1 month and 3 months interval using VAS. In immediate postoperative period the mean VAS scores were 3.46 (12 hrs) and 1.65 (24 hours). In our study at the time of 3 months' follow up only 1 patient (1.5%) had mild pain while 98.5% patients were having no pain. Similar results were reported by Bell RC et al.,¹⁴ and Iqbal SM¹⁵ who reported mild pain in 1% and 3.70% patients at the time of 3 months follow up.

The analysis of postoperative complications showed that the most common complication in this study was seroma which was seen in 8 (12.6%) patients followed by pneumoscrotum and peritoneal breach. Comparable results were reported by Ashraf Z et al.,¹⁶ who reported incidence of seroma in 4 patients (5.8%). In our study urinary retention was found in 1 (1.5%) patients. Similar incidence of urinary retention following laparoscopic hernia repair were reported by Ramshaw BJ et al.,¹⁷ (1.6%) and Najib Khoury et al. (1.8%).¹⁸

Majority of our patients (96.8%) could be discharged within 24 hours after surgery. Despite having minimal complications patient could be discharged and was advised to come for follow up. Only 2 patients (3.1%) had to be kept hospitalized for more than 24 hours owing to pain. Similar duration of hospital stay was reported by Palanivelu et al., who reported that majority of the patients, could be discharged from hospital within 1 day after surgery for inguinal hernia repair.¹⁹

Mean time required for ambulation in our study was found to be 5.04 ± 1.83 hours. Amongst the studied cases in this study no patient developed recurrence over a period of

6 months follow up. Similar recurrence rate was reported by E.H. Phillips, et al., conducted a study of 68 hernia repairs performed in 35 patients. The first 25 patients were kept overnight for observation and discharged the following day. The authors reported that thirty-two patients (92%) were able to resume full physical activity within 1 week. Average follow-up was 12 months and there were no incidences of recurrence of hernia in any of the studied cases.²⁰

CONCLUSION

Laparoscopic TEP inguinal hernia repair using an anatomically contoured 3D mesh is a safe and effective technique of hernia repair. It has a technical advantage of easy insertion in an anatomically correct position with no fixation and is found to be associated with significant pain reduction and a remarkable reduction in hernia recurrence.

REFERENCES

1. Tan WP, Lavu H, Rosato EL, Yeo CJ and Cowan SW. Edoardo Bassini (1844-1924): father of modern-day hernia surgery. *Am Surg.* 2013; 79(11):1131-1133. <https://doi.org/10.1177/000313481307901112>
2. Wantz GE. Giant prosthetic reinforcement of the visceral sac. *Surg Gynecol Obstet.* 1989; 169(5):408-417.
3. Ger R. Laparoskopische Hernienoperation [Laparoscopic hernia operation]. *Chirurg.* 1991;62(4):266-270. German.
4. Salvilla SA, Thusu S and Panesar SS. Analysing the benefits of laparoscopic hernia repair compared to open repair: A meta-analysis of observational studies. *J Minim Access Surg.* 2012; 8(4):111-117. <https://doi.org/10.4103/0972-9941.103107>
5. Chowbey PK, Pithawala M, Khullar R, Sharma A, Soni V and Baijal M. Complications in groin hernia surgery and the way out. *J Minim Access Surg.* 2006; 2(3):174-177. <https://doi.org/10.4103/0972-9941.27734>
6. Sajid MS, Bokhari SA, Mallick AS, Cheek E and Baig MK. Laparoscopic versus open repair of incisional/ventral hernia: a meta-analysis. *Am J Surg.* 2009; 197(1):64-72. <https://doi.org/10.1016/j.amjsurg.2007.12.051>
7. Read RC. Preperitoneal herniorrhaphy: a historical review. *World J Surg.* 1989; 13(5):532-539; discussion 539-540. <https://doi.org/10.1007/BF01658866>
8. Doctor HG. Evaluation of various prosthetic materials and newer meshes for hernia repairs. *J Minim Access Surg.* 2006; 2(3):110-116. <https://doi.org/10.4103/0972-9941.27721>
9. Campanelli G, Pettinari D, Cavalli M and Avesani EC. Inguinal hernia recurrence: Classification and approach. *J Minim Access Surg.* 2006; 2(3):147-150. <https://doi.org/10.4103/0972-9941.27728>
10. Pajotin P. Laparoscopic Groin Hernia Repair Using a Curved Prosthesis without Fixation. *Le Journal de Celio – Chirurgie.* 1998;28:64-68.
11. Amato G, Romano G, Agrusa A, Cocorullo G, Gulotta G and Goetze T. Dynamic inguinal hernia repair with a 3d fixation-free and motion-compliant implant: a clinical study. *Surg Technol Int.* 2014; 24:155-165.

12. Hamza Y, Gabr E, Hammadi H and Khalil R. Four-arm randomized trial comparing laparoscopic and open hernia repairs. *Int J Surg.* 2010; 8(1):25-28.
<https://doi.org/10.1016/j.ijso.2009.09.010>
13. McCormack K, Wake BL, Fraser C, Vale L, Perez J and Grant A. Transabdominal pre-peritoneal (TAPP) versus totally extraperitoneal (TEP) laparoscopic techniques for inguinal hernia repair: a systematic review. *Hernia.* 2005; 9(2):109-114.
<https://doi.org/10.1007/s10029-004-0309-3>
14. Bell RC and Price JG. Laparoscopic inguinal hernia repair using an anatomically contoured three-dimensional mesh. *Surg Endosc.* 2003; 17(11):1784-1788.
<https://doi.org/10.1007/s00464-002-8763-4>
15. Iqbal SM, Alfer AN, Aijaz AM, Muntakhab N, Yawar W, Farooq M, et al. An Experience of Short –term Results of Laparoscopic Inguinal Hernioplasty Using 3D MESH. *International Journal of Clinical Medicine.* 2015; 6(1): 64-69.
<https://doi.org/10.4236/ijcm.2015.61010>
16. Zeineldin A. Transabdominal (TAPP) versus Total extraperitoneal (TEP) laparoscopic inguinal hernia repair: a prospective comparative study. *Menoufiya Medical Journal.* 2008; 147:Vol. 21 No. 2.
17. Ramshaw BJ, Tucker JG, Mason EM, Duncan TD, Wilson JP, Angood PB, et al. A comparison of transabdominal preperitoneal (TAPP) and total extraperitoneal approach (TEPA) laparoscopic herniorrhaphies. Department of Surgery, Georgia Baptist Medical Center, Atlanta 30312. 1995; 61(3):279-283.
18. Khoury N. A comparative study of laparoscopic extraperitoneal and transabdominal preperitoneal herniorrhaphy. *J Laparoendosc Surg.* 1995; 5(6):349-355.
<https://doi.org/10.1089/lps.1995.5.349>
19. Palanivelu, Chapter 10, Operative Manual of Laparoscopic Surgery, 140- 141.
20. Phillips EH. Laparoscopic inguinal herniorrhaphy. *Springer Endoscopy Vol 9, Number1/1995;16-21.*


Authors Contribution:

NM-Concept and design of the study; interpreted the results, prepared first draft of manuscript and critical revision of the manuscript, Statistically analyzed and interpreted; reviewed the literature and manuscript preparation; **DG**- Design of the study, statistically analyzed and interpreted, preparation of manuscript and revision of the manuscript, Concept and coordination of the overall study.

Work Attributed to:

Government Medical College, Chandrapur, Maharashtra.

Orcid ID:

Dr. Nilesh Mangam-  <https://orcid.org/0000-0002-7522-9198>

Source of Funding: None, **Conflict of Interest:** None.