

A rare case of tuberculoma masquerading as CP Angle neoplasm



Sinjan Ghosh¹, Gautam Guha², Kaushik Roy³, Anness Bhattacharjee⁴, Nikhil Repaka⁵, Sourav Nanda⁶, Niraja Agasti⁷

^{1,4,5,6,7}Neurology Resident, ²Associate Professor, Department of Neurology, Nil Ratan Sircar Medical College and Hospital, Kolkata, West Bengal, India, ³Associate Professor, Department of Neurosurgery, Nil Ratan Sircar Medical College and Hospital, Kolkata

Submitted: 20-05-2019

Revised: 28-05-2019

Published: 01-07-2019

ABSTRACT

Tuberculoma involving the cerebellopontine angle is very rare. Preoperative neuroradiological features of such lesions may mimic neoplastic lesions. Our case presented with cerebellar features and multiple cranial nerve palsy. Neuroimaging mimicked CP angle neoplastic lesion. Antitubercular therapy and steroids resulted in significant clinical improvement and marked radiological reduction in size of the lesion. In our subcontinent a treatable infective cause like tuberculosis should be ruled out in CP angle lesions. Although rare but definitely a possibility to be considered.

Key words: CP Angle SOL; Tuberculoma; CNS Tuberculosis; Tuberculosis radiology

Access this article online

Website:

<http://nepjol.info/index.php/AJMS>

DOI: 10.3126/ajms.v10i4.24169

E-ISSN: 2091-0576

P-ISSN: 2467-9100

INTRODUCTION

Approximately 10-15% of all patients with tuberculosis have central nervous system (CNS) involvement¹ and it is seen most commonly in the developing countries. Although large series from developing countries continue to be reported² and incidence has increased for the last 20 years due to human immunodeficiency virus (HIV) infection, people of any age can be affected and the mycobacterium usually reaches the CNS by haematogenous dissemination from pulmonary lesions.

Tuberculoma is found in 15-30% of cases of CNS tuberculosis³ and is hemispheric in most cases². Other, rare locations include the sellar area, cerebellopontine angle, Meckel's cave, suprasellar cistern, and hypothalamic region^{3,4}.

Central nervous system tuberculoma presenting as a solitary mass is rare in an extrinsic location. The cerebellopontine angle is a very unusual site for tuberculoma⁵. Only a few reports have been published in the literature.

CASE REPORT

A 47 yrs old normotensive and euglycemic right handed gentleman presented with a subacute onset progressively

increasing left hemicranial headache with low grade intermittent fever for 4 months.

The headache was dull aching and occasionally throbbing in character and of moderate to severe in intensity. Within 3 weeks he developed facial deviation towards the right side with diminished hearing in his left ear with speech discrimination more affected than pure tones. Within 1 week this was followed by tremulousness of limbs and gait imbalance with tendency to fall towards the left side.

There was a background history of tremulousness of head and limbs for long 20yrs with similar history in his father. There was no history suggestive of cognitive affection, sphincter complains, bulbar or sensory involvement.

On Clinical examination, patient was conscious oriented with dysarthric speech. Saccades slow with broken pursuits and gaze evoked nystagmus with fast component to the left side. Left LMN facial palsy and mixed (Conductive and Sensorineural) deafness in left ear. Features consistent with left sided vestibular affection was also noted. Motor power was 4/5 in right upper and lower limbs with normal power in left side. Postural tremor was noted in bilateral upper limbs (right more than left) with dystonic posturing and in left upper limb intention tremor was present. Head

Address for Correspondence:

Dr. Sinjan Ghosh, Resident, Nil Ratan Sircar Medical College and Hospital, Kolkata, West Bengal, India. **Phone:** +91 -9433295789.

E-mail: drsinjan@gmail.com

© Copyright AJMS

tremor was also noted. Sensory system examination was normal. Deep tendon reflexes were preserved with left plantar flexor and right plantar was equivocal. Left sided cerebellar signs were elicited. He had a wide based lurching and ataxic gait. Meningeal signs were absent. Cranium and spine examination was within normal limits.

On routine lab investigations ESR was 82mm in 1st hr and Mantoux test was positive. Other investigations including Chest X ray were normal.

MRI Brain (Plain and Contrast) [08/10/2018] showed extra axial SOL in Left CP Angle with intracanalicular extension along with meningeal enhancement and perilesional edema (Figure 1 and 2). Although the neuroimaging was reminiscent of a CP angle neoplastic SOL, the clinical profile and minute observation of the lesion evoked a suspicion of infective pathology consistent with a chronic granulomatous inflammation. A tissue diagnosis was planned but the patient and his caregivers refused to go for surgical exploration considering the probable inadvertent consequences.

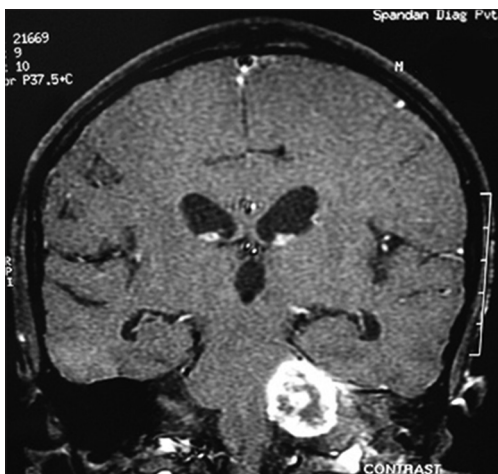


Figure 1: Left CP angle SOL- T1 post contrast image

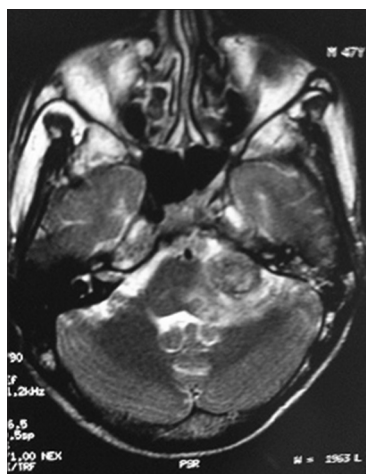

Figure 2: Left CP angle SOL with edema in T2W axial image

On high clinical suspicion anti tubercular therapy with steroid was administered as per protocol and MR Spectroscopy of the lesion was ordered. MR Spectroscopy and high (Figure 3a and 3b) ESR was supportive of a Tubercular etiology in this case. In the course of treatment his headache and other symptoms subsided.

A repeat MRI Brain (Plain and Contrast) after 1 month of ATD revealed- The lesion in left CP Angle got reduced in size with resolving perilesional edema as compared to the previous MRI Figure 4.

This report was corroborating with the clinical improvement. He was discharged with mild head and upper limb tremor which was present since long and was familial. A residual left LMN Facial palsy and mixed deafness in left ear persisted. He is on follow up and doing well clinically.

DISCUSSION

With the increasing number of tuberculosis cases, CNS tuberculosis is also increasing with 3-5% cases presenting with isolated CNS affection without pulmonary involvement.⁵

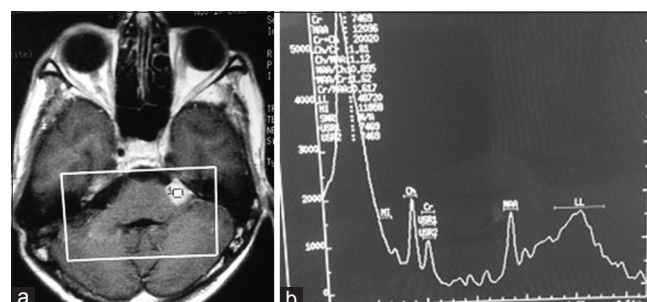


Figure 3: (a) MRS voxel on CP angle SOL (b) MRS on lesion showing lipid lactate peak

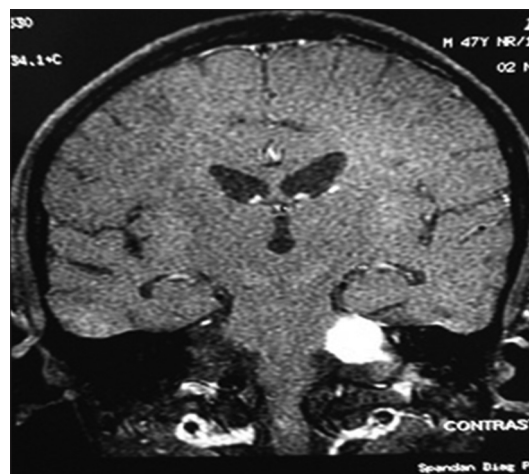


Figure 4: Post ATD treatment reduction in size of SOL-post contrast

Tuberculosis involving the leptomeninges, brain and skull base is thought to spread by haematogenous dissemination from a primary source outside the CNS. The meningitic process may affect the cranial cerebrospinal fluid (CSF) pathway, the spinal subarachnoid pathway, or both⁶. Parenchymal disease usually presents as either solitary or multiple tuberculoma, and can occur with or without meningitis⁷. Tuberculomas are histologically round or oval masses, or they may assume a more lobular configuration with the fusion of several smaller nodules.³

In the present case the classical features were lacking.

Only ten percent of CNS TB are associated with concomitant meningitis⁸. We did not perform a CSF study, but there were no clinical evidence of meningitis or intraventricular lesions apart from a small lesion in left paraventricular region suggestive of an isolated tuberculoma. On meticulous observation the CP angle SOL showed multiple conglomerated ring enhancing lesions with perilesional edema.

Confirmation of CNS tuberculosis is only possible by isolation of Mycobacterium or histopathological identification of tuberculous granuloma. In all cases tissue diagnosis is not possible and ATD is initiated on the basis of strong clinical suspicion. Various investigations including CT scan, MRI, magnetization transfer MRI, or in vivo proton MR-spectroscopy⁹ have been suggested.

The inappropriate neuroradiological diagnosis of meningioma, neurinoma, or even metastasis is usual in cases of tuberculoma¹⁰. Cerebellopontine angle tumours are most common lyacoustic schwannomas or meningiomas⁵. Other differential diagnoses include cholesteatoma, metastases, lymphoma, brain abscess, fungal infection, neurocysticercosis, sarcoidosis, etc. Tuberculomas occurring as isolated masses in the cerebellopontine angle are extremely rare, with only two cases reported, both of which were in the pre-MRI era⁵ followed by a very few cases reported after that.

CONCLUSION

The uniqueness of our case is the rare presentation of a treatable infective pathology radiologically masquerading as a neoplastic SOL. The histopathological evidence could not be confirmed as the patient refused any surgical intervention but the clinical pointers and epidemiological probability being high, ATD was administered. The MR Spectroscopy was supportive and the therapeutic response was the clincher in this case.

REFERENCES

1. Prabhakar S., Thussu A. Central nervous system tuberculosis. *Neurol India* 1997; 45: 132-140.
2. Arvind C., & Korath M.P., Raveendranadhan, K & Jagadeesan, K. A retrospective study of 1247 cases of intracranial tuberculomata diagnosed by computerized tomography. *J Assoc Physicians India* 1993; 41: 559-61.
3. de Castro C.C., de Barros N.G., Campos Z.M., Cerri GG. CT scans of cranial tuberculosis. *Radiol Clin North Am* 1995;33: 753-769.
4. Goel A., Nadkarni T., Desai A.P. Tuberculoma in the Meckel's cave: a case report. *Neurol India* 1999; 47: 238-240.
5. Sathyanarayana S., Baskaya M.K., Fowler M., Roberts R., Nanda A. Solitary tuberculoma of the cerebellopontine angle: a rare presentation. *J Clin Neurosci* 2003; 10: 120-122.
6. Khoo J.L.S., Lau K.Y., Cheung C.M., Tso T. H. Central nervous system tuberculosis. *J HK Coll Radiol* 2003; 6: 217-228.
7. Jinkins J.R. Computed tomography of intracranial tuberculosis. *Neuroradiology* 1991; 33: 126-135.
8. Giese A., Kucinski T., & Hagel C., & Lohmann F. Intracranial tuberculomas mimicking a malignant disease in an immunocompetent patient. *Acta Neurochir* 2003. 145. 513-7; discussion 517.
9. Gupta R.K., Husain M., Atsal D.K., Kumar R., Chawla S., Husain N. Comparative evaluation of magnetization transfer MR imaging and in vivo MR spectroscopy in brain tuberculomas. *Magn Reson Imaging* 2002; 20: 375-381.
10. Yanardag H., Uygun S., Yumuk V., Caner M., Canbaz B. Cerebral tuberculosis mimicking intracranial tumour. *Singapore Med J* 2005; 46: 731.

Authors Contribution:

SG and KR: Concept and design of the study, reviewed the literature, manuscript preparation and critical revision of the manuscript; **GG:** Concept, collected data and review of literature and helped in preparing first draft of manuscript; **AB and NR:** Conceptualized study, literature search, statistically analyzed and interpreted, prepared first draft of manuscript; **SN and NA:** Concept of study, collected data and review of study.

Work attributed to:

Department of Neurology, Nil Ratan Sircar Medical College and Hospital, Kolkata, West Bengal, India

Orcid ID:

Dr. Sinjan Ghosh- <https://orcid.org/0000-0003-2416-3181>
 Dr. Gautam Guha- <https://orcid.org/0000-0002-8902-2817>
 Dr. Kaushik Roy- <https://orcid.org/0000-0001-8317-9840>
 Dr. Anshu Bhattacharjee- <http://orcid.org/0000-0001-6560-2692>
 Dr. Nikhil Repaka- <http://orcid.org/0000-0002-3856-8940>
 Dr. Sourav Nanda- <http://orcid.org/0000-0003-2049-8208>
 Dr. Niraja Agasti- <http://orcid.org/0000-0001-5884-719X>

Source of Support: Government of West Bengal, India, **Conflict of Interest:** None declared.