

# Skin tag: a mimicker of Solitary pulmonary nodule



Submitted: 13-04-2018

Revised: 19-04-2018

Published: 01-05-2018

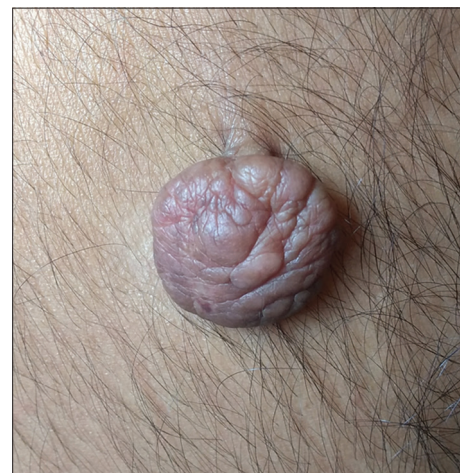Dear Sir,

A solitary pulmonary nodule (SPN) is a frequent finding on chest radiography these days. Since SPN is an alarming sign for lung cancer, clinicians go in for a battery of investigations. However, these lesions can have mimics.

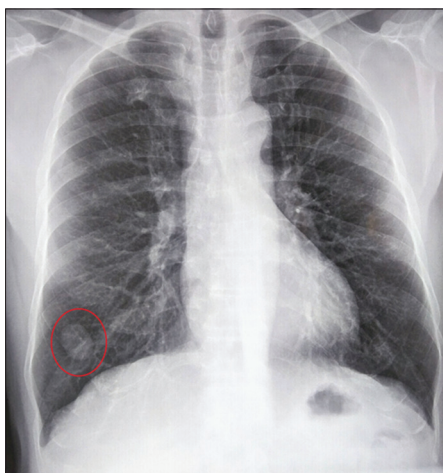
A 60 year old male, shopkeeper, with no comorbid condition, was referred to our centre with the diagnosis of SPN. The patient had taken up a routine health check-up package which included a chest Xray; and a well-defined nodular lesion (5 x 4 mm) was noted in the right lower zone (Figure 1). He was a non-smoker and did not have any respiratory symptoms. He was anxious, with stable vitals. He had a large skin tag over the right side of his back, which has been present since childhood with no change in size (Figure 2). His systemic examinations were normal. His blood investigations like complete blood counts, ESR, HbA1c, renal and liver functions (which were done in the health check-up package) were normal. A lateral Xray of the chest showed the skin tag (Figure 3). The patient was assured that it was the skin lesion that mimicked SPN. However, he insisted on a computed tomography (CT) of the thorax, which was normal.

According to the Nomenclature Committee of the Fleischner Society, a pulmonary nodule is a well or poorly

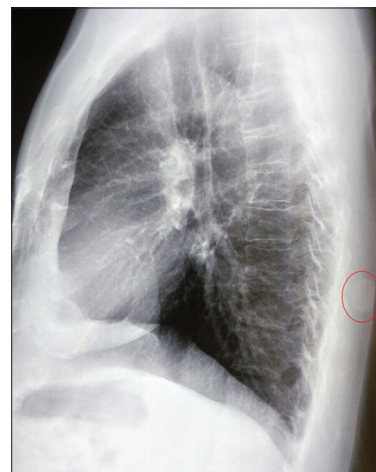defined rounded opacity on conventional radiography, measuring up to 3 cm in diameter. The findings are similar on CT thorax.<sup>1</sup> These lesions are found incidentally in 0.09–0.2% of all chest radiographs. Opacity less than 3 mm is termed as a micronodule.<sup>2</sup> The incidence of SPN is 8–51%.<sup>3,4</sup> Hamartomas and infectious granulomas are

**Access this article online****Website:**<http://nepjol.info/index.php/AJMS>**DOI: 10.3126/ajms.v9i3.19617****E-ISSN: 2091-0576****P-ISSN: 2467-9100**

**Figure 2:** Skin tag over the right side of the back



**Figure 1:** Chest Xray (PA view) showing a well-defined nodular lesion in the right lower zone



**Figure 3:** Chest Xray (lateral view) showing the skin tag

considered benign; while malignant lesions include primary lung cancer, carcinoid tumours, and lung metastases.<sup>5</sup> Pulmonary pseudonodules, skin lesion, a device outside the patient and anatomic variants can mimic SPN.<sup>2</sup>

This case highlights the importance of general examination to rule out mimics of SPN like skin lesions before ordering investigations like CT. In most cases, a lateral chest Xray would be sufficient to establish the diagnosis of SPN mimics. This would also help to avoid panic of lung cancer among patients.

**Key words:** Solitary pulmonary nodule, Skin tag, Lung nodule

**Robin George Manappallil<sup>1</sup>,  
Mele Chelakkoth Sabir<sup>2</sup>, Aryashree Kakkattil<sup>3</sup>**

<sup>1</sup>Consultant, Department of Internal Medicine, Baby Memorial Hospital, Calicut, Kerala 673004, India, <sup>2</sup>Consultant, Department of Pulmonary Medicine, Baby Memorial Hospital, Calicut, Kerala 673004, India, <sup>3</sup>Resident, Department of Internal Medicine, Baby Memorial Hospital, Calicut, Kerala 673004, India

**Address for correspondence:**  
Dr. Robin George Manappallil, Consultant,

Department of Internal Medicine, Baby Memorial Hospital,  
Calicut, Kerala 673004, India  
**Mobile:** +91-8547753396  
**E-mail:** drrobingeorgempl@gmail.com

## REFERENCES

1. Hansell DM, Bankier AA, MacMahon H, McLoud TC, Müller NL and Remy J. Fleischner Society: glossary of terms for thoracic imaging. *Radiology* 2008; 246(3):697-722.
2. Holin SN, Dwork RE, Glaser S, Rikli AE and Stocklen JB. Solitary pulmonary nodules found in a community-wide chest roentgenographic survey; a five-year follow-up study. *Am Rev Tuberc* 1959; 79:427-439.
3. Swensen SJ, Jett JR, Hartman TE, Midthun DE, Sloan JA, Sykes AM, et al. Lung cancer screening with CT: Mayo Clinic experience. *Radiology* 2003; 226:756-761.
4. Gohagan J, Marcus P, Fagerstrom R, Pinsky P, Kramer B and Prorok P. Writing Committee, Lung Screening Study Research Group. Baseline findings of a randomized feasibility trial of lung cancer screening with spiral CT scan vs chest radiograph: the Lung Screening Study of the National Cancer Institute. *Chest* 2004; 12:114-121.
5. Gould MK, Fletcher J, Iannettoni MD, Lynch WR, Midthun DE, Naidich DP, et al. Evaluation of patients with pulmonary nodules: when is it lung cancer?: ACCP evidence-based clinical practice guidelines 2<sup>nd</sup> ed. *Chest*. 2007; 132(3 suppl):108S-130S.

### Authors Contribution:

**RGM**- Concept and design of case report, reviewed the literature, manuscript preparation and treating physician; **MCS**- Critical revision of the manuscript and treating pulmonologist; **AK**- Resident in charge.

### Orcid ID:

Dr. Robin George Manappallil -  <http://orcid.org/0000-0003-3973-6800>

**Source of Support:** Nil, **Conflict of Interest:** None declared.