

Stenotrophomonas maltophilia: an unusual pathogen for pneumonia in an immunocompetent patient



Submitted: 06-08-2017

Revised: 27-08-2017

Published: 01-11-2017

Sir,

Stenotrophomonas maltophilia, previously known as *Pseudomonas maltophilia*, is a saprophyte and an opportunistic pathogen. In comparison to *Pseudomonas aeruginosa*, its ability to colonize patients or cause infections is limited.¹

A 45 year old male, with no comorbidities, was referred from a local hospital with the diagnosis of lower respiratory tract infection. He had 7 days history of fever with chills and dry cough. He had received intravenous ceftriaxone and oral doxycycline for 4 days; but there was no relief of symptoms.

On presentation, he was conscious and oriented, with a temperature of 101°F. His heart rate was 100/minute, blood pressure 110/70mmHg, respiratory rate 28/minute and saturation 90% in room air. His systemic examinations revealed right sided lung crepitations and associated rhonchi. Chest Xray showed right upper and middle zone consolidation (Figure 1) with was confirmed on CT thorax. His blood investigations showed leucocytosis (18,200/cmm) with neutrophilia (N94 L4 E2). Renal and liver parameters, electrolytes, PT/INR and aPTT were normal. He was started on intravenous meropenem (500mg q8h), oral clarithromycin (500mg twice daily) and oral linezolid (600mg twice daily) along with bronchodilator nebulizations. On day 3 of admission, his condition remained unchanged. His total counts became 22,600/cmm. Throat swab for H1N1 and Mantoux test was negative. Blood cultures were sterile. Bronchoscopy was done and broncho alveolar lavage culture grew *Stenotrophomonas maltophilia*; which was resistant to all antibiotics (including carbapenems) except levofloxacin and trimethoprim-sulfamethoxazole (TMP-SMX). Meropenem, linezolid and clarithromycin were stopped, and the patient was started on intravenous levofloxacin (750mg once daily) and double strength TMP-SMX (twice daily) orally. By day 6 of admission, his respiratory rate became 20/minute and saturation 96% (room air). Total counts also started normalizing;

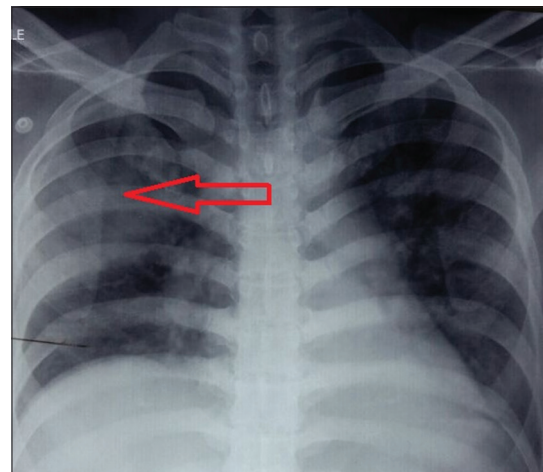
Access this article online**Website:**<http://nepjol.info/index.php/AJMS>**DOI: 10.3126/ajms.v8i6.17959****E-ISSN: 2091-0576****P-ISSN: 2467-9100**

Figure 1: Chest Xray showing right upper and middle zone consolidation

and patient was discharged on day 10 of admission in stable condition.

Stenotrophomonas maltophilia infections are commonly seen in immunocompromised patients. These organisms show resistance to broad spectrum antibiotics like carbapenems and advanced cephalosporins. This is due to the possession of antibiotic efflux pumps and L1 and L2 β -lactamases which cause β -lactam resistance. These organisms are commonly seen in respiratory tract of ventilated patients, thereby causing ventilator associated pneumonia. Central venous catheter associated infections have been noticed in cancer patients. These organisms are usually susceptible to TMP-SMX, levofloxacin, ticarcillin-clavulanate and tigecycline.¹

Septicemia with *Stenotrophomonas maltophilia* is rather uncommon. The cases reported include endocarditis,

meningitis, skin lesions, intra-abdominal abscess, elbow infection, pneumonia, otitis externa, dacryocystitis and keratitis.²⁻¹⁰ However, in most of these cases, the patients had undergone a procedure or had an immunocompromised state. Our patient was immunocompetent and had no history of interventional procedures or implants. This case, therefore, highlights the emergence of *Stenotrophomonas maltophilia* as a pathogen for pneumonia in immunocompetent patients, and its consideration in patients not responding to broad spectrum antibiotics.

Key words: *Stenotrophomonas maltophilia*, Pneumonia, Carbapenems

**Robin George Manappallil¹,
Mele Chelakkoth Sabir²**

¹Consultant, Department of Internal Medicine, Baby Memorial Hospital, Calicut, Kerala 673004, India, ²Consultant, Department of Pulmonary Medicine, Baby Memorial Hospital, Calicut, Kerala 673004, India

Address for correspondence:

Robin George Manappallil, Consultant,
Department of Internal Medicine, Baby Memorial Hospital,
Calicut, Kerala 673004, India. **Tel:** 0091-8547753396.
E-mail: drrobingeorgempl@gmail.com

REFERENCES

- Ramphal R. Infections Due to *Pseudomonas* Species and Related Organisms In: Kasper, Fauci, Hauser, Longo, Jameson, Loscalzo (ed). Harrison's Principles of Internal Medicine. 19th ed. McGraw Hill education. pp. 1048.
- Gutiérrez Rodero F, Masiá MM, Cortés J, Ortiz de la Tabla V, Mainar V and Vilar A. Endocarditis caused by *Stenotrophomonas maltophilia*: case report and review. *Clin Infect Dis* 1996; 23(6):1261-1265.
- Yemisen M, Mete B, Tunali Y, Yentur E and Ozturk R. A meningitis case due to *Stenotrophomonas maltophilia* and review of the literature. *Int J Infect Dis* 2008; 23: 1-3.
- Teo WY, Chan MY, Lam CM and Chong CY. Skin manifestation of *Stenotrophomonas maltophilia* infection--a case report and review article. *Ann Acad Med Singapore* 2006; 35(12):897-900.
- Lim DR, Kuk JC, Kim T and Shin EJ. Unusual case of rapid growing intraabdominal abscess caused by *Stenotrophomonas maltophilia* after laparoscopic appendectomy due to perforated appendicitis: A case report. *Medicine (Baltimore)*. 2017;96(20):e6913.
- Yamaguchi K, Adams R and Morrey B. Infection after total elbow arthroplasty. *J Bone Joint Surg Am* 1998; 80:481-491.
- Gasparetto EL, Bertholdo DB, Davaus T, Marchiori E and Escuissato DL. *Stenotrophomonas maltophilia* pneumonia after bone marrow transplantation: case report with emphasis on the high-resolution CT findings. *Br J Radiol* 2007;80(949):e19-e20.
- Al-Ghamdi KB, Rammal AA and Sindi RS. Otitis externa due to *Stenotrophomonas maltophilia* in an immune competent patient: Case report. *Journal of Infectious Diseases and Immunity* 2012;4(2): 20-22.
- Wladis EJ. Dacryocystitis secondary to *Stenotrophomonas maltophilia* infection. *Ophthal Plast Reconstr Surg* 2011; 27(5):e116-e117.
- Holifield K and Lazzaro DR. Case report: spontaneous *Stenotrophomonas maltophilia* keratitis in a diabetic patient. *Eye Contact Lens* 2011;37(5):326-327.

Authors Contribution:

RGM- Concept and design of case report, reviewed the literature, manuscript preparation and treating physician; **MCS**- Critical revision of the manuscript and treating pulmonologist.

ORCID ID:

Dr. Robin George Manappallil -  <http://orcid.org/0000-0003-3973-6800>

Source of Support: Nil, **Conflict of Interest:** None declared.