

Analyzing the variability of craniometric parameters using computed tomography scan in the Indian Population



Sandeep BV¹, Raj Swaroop Lavadi², Manpreet Singh Banga³, Sangamesh Halhalli⁴, Anantha Kishan⁵, Hiba Salam⁶

^{1,3}Assistant Professor, ^{2,6}Intern Medical Officer, ⁴Senior Resident, ⁵Professor and Head, Department of Neurosurgery, Vydehi Institute of Medical Sciences and Research Centre, Bengaluru, Karnataka, India

Submission: 27-07-2022

Revision: 29-09-2022

Publication: 01-11-2022

ABSTRACT

Background: The craniovertebral junction (CVJ) is a crucial region of the spine designed for optimal movements of the head and is also a frequent site for various pathological processes. The importance of knowing the CVJ parameters in the normal population cannot be overstated when instrumentation and correction of deformities in this region is so frequently being performed. There is a paucity of data defining the craniometrics of CVJ osteology in the Indian population on the literature search. Accordingly, we present a study in an attempt to quantitate the normal craniometric indices for an anatomically normal CVJ in the Indian population and compare them with the existing literature from other regions. **Aims and Objectives:** The aims of this study were to quantitate the normal craniometric indices for anatomically normal CVJ in Indian population and compare them with the existing literature from other regions. **Materials and Methods:** Two hundred and forty computed tomography (CTs) belonging to Indians were looked at over a 6-month period retrospectively. These patients had normal CVJs and were ordered imaging for other health reasons. A total of eight parameters were analyzed for each CT. **Results:** There were 166 (69.2%) males and 74 (30.8%) females in our study. The values (in mm) were as follows: anterior atlantodental interval (AADI), 1.78 ± 0.42 ; PADI (posterior atlantodental interval), 18.12 ± 1.97 ; distance of tip of odontoid process to chamberlain's line, -2.73 ± 2.63 ; distance of tip of odontoid process to McGregor's line, -2.29 ± 2.79 ; distance of tip of odontoid process to McRae's line, -5.91 ± 1.4 ; Clivus-canal angle, $160.82^\circ \pm 7.14^\circ$; basion dens interval, 5.6 ± 1.45 ; and powers ratio, 0.71 ± 0.07 . No patient had an odontoid process extending beyond the McRae's line. Males were more likely to have higher AADI and PADI values than females. Our study shared significant differences between the other studies (even the studies where an Indian population was used) except one. The AADI, from our study, did not vary significantly when compared to the AADI from a Chinese study. **Conclusion:** Due to the significant differences from our study and the available literature, a greater compilation of studies belonging to different races will be required to understand the flexibility of the CVJ metrics.

Key words: Craniovertebral junction; Craniometry; Skull base; Computed tomography

INTRODUCTION

The craniovertebral junction (CVJ) is a crucial region of the spine designed for optimal movements of the head. Apart from offering support, the CVJ provides a passageway allowing smooth transition of vital neural structures to the lower body. Extending from the basiocciput to the

C₂ interspace,¹ the CVJ is supported by ligaments and articulations between the occiput, atlas, and axis vertebrae. It is a frequent site for various pathological processes, some of which are unique to the location. Being a transitional zone, developmental variations and malformations are often noted in this region. Most authors who have studied CVJ parameters have included patients with congenital bony

Access this article online

Website:

<http://nepjol.info/index.php/AJMS>

DOI: 10.3126/ajms.v13i11.14585

E-ISSN: 2091-0576

P-ISSN: 2467-9100

Copyright (c) 2022 Asian Journal of Medical Sciences



This work is licensed under a Creative Commons Attribution-NonCommercial 4.0 International License.

Address for Correspondence:

Manpreet Singh Banga, Department of Neurosurgery, Vydehi Institute of Medical Sciences and Research Centre, Bengaluru - 560 066, Karnataka, India. **Mobile:** +91-8979112233. **E-mail:** dr.msbanga@gmail.com

CVJ anomalies or patients with Chiari malformation.²⁻⁴ The importance of knowing the CVJ parameters in the normal population cannot be overstated when instrumentation and correction of deformities in this region are so frequently being performed. There is a paucity of data defining the craniometrics of CVJ osteology in the Indian population on literature search. Most of the data available is based on plain X-ray images and in the era of computed tomography (CT), more studies are required for accurate measurement of craniometrics of this complex region.

Accordingly, we present a study in an attempt to quantitate the normal craniometric indices for anatomically normal CVJ in the Indian population and compare them with the existing literature from other regions.

Aims and objectives

The aims of this study were to quantitate the normal craniometric indices for an anatomically normal CVJ in the Indian population and compare them with the existing literature from other regions.

MATERIALS AND METHODS

An observational retrospective analysis was conducted in the Department of Neurosurgery at Vydehi Institute of Medical Sciences and Research Center, Bangalore, India. As the present study is retrospective in nature, patient consent and ethical clearance were not required.

The data was collected over a 6-month interval. We included all the patients who underwent a CT brain and cervical spine for various causes but reported a normal CT cervical spine. To be specific, we included only those CTs that met the requirements of the normal craniometric parameters that were to be assessed in this study. Patients having prior history of any neurological deficit or any cervical spine pathology on CT cervical spine were not included in the study. Patients with age group of <18 years were also excluded. A total of 240 Indian patients were included in the study. The machine used was a Siemens Somatom Definition AS (128 slice machine). Sagittal sections were obtained at 0.5 mm slice thickness and analyzed in the bone window setting. The following measurements were taken with in-built linear calipers on picture archiving and communication systems. The parameters we intend to measure have been mentioned below along with their definitions and their normal benchmark as indicated by previous literature.

1. Anterior atlantodental interval (AADI): Horizontal distance from the posterior margin of of the anterior arch of the atlas to the anterior margin of the odontoid process of axis. This was measured in midline sagittal

cuts of CT scan. It was similar to the measurement done by Selçuk et al.⁵ If the value was <3 mm, it was taken to be normal⁶

2. Posterior atlantodental interval (PADI): Horizontal distance from the anterior margin of posterior arch of the atlas to the posterior margin of the odontoid process of axis in the mid-sagittal section, which is similar to the definition by Boden et al.⁷ If the value was ≥ 14 mm, the value was taken to be normal⁸
3. Distance of tip of odontoid process to Chamberlain's line (dCL): Chamberlain's line⁹ is drawn from the posterior end of the hard palate to the posterior margin of the foramen magnum. A perpendicular line is drawn from Chamberlain's line to the tip of odontoid and the distance was measured. A value of <6.6 mm projection of the odontoid tip above the Chamberlain's line was considered to be normal¹⁰
4. Distance of tip of odontoid process to McGregor's line (dMG): McGregor's line¹¹ is drawn from the posterosuperior margin of the hard palate to the lowest point of the midline occipital curve. A perpendicular line is drawn from McGregor's line to the tip of odontoid and the distance was measured. If the odontoid process was positioned <4.5 mm above this line, the value was considered to be normal.¹⁰
5. Distance of tip of odontoid process to McRae's line (dMR): McRae's line¹² is the foramen magnum line joining the basion and opisthion. A perpendicular line is drawn from McRae's line to the tip of odontoid and the distance was measured. If the odontoid process did not project above this line, the parameter was considered to be normal¹⁰
6. Clivus-canal angle (CCA): Measured as the angle at the intersection of a line extending from the inferior one-third of the clivus and a line extending from the inferodorsal portion of the C-2 vertebral body to the superodorsal part of the dens.¹³ Smoker has considered a normal value to lie between 150° and 180°¹⁴
7. Basion dens interval (BDI): Measured as the distance between the basion and the tip of the odontoid process. If the value was <8.5 mm, it was considered to be normal¹⁵
8. Powers ratio (PR): PR was considered to be the distance between the basion and the posterior arch of C1 divided by the distance between the opisthion and the midpoint of the posterior aspect of the anterior arch of C1. A value of <1 was considered to be normal.¹⁵

Figures 1-5 show how the parameters were measured for the present study.

Statistical analysis

SSPS version 22 was used to analyze the results. We calculated the mean and standard deviation for all the

parameters. We calculated P-values to assess statistical significance between our values and the values available in the existing literature along with identifying any difference between males and females in the present study. One sample t-test/Wilcoxon Sign-Rank test was used to compare the means and medians, respectively. Independent sample t-test/Mann-Whitney U-test was used to compare the parameters between males and females depending on the distribution of the data.

RESULTS

A total of 240 CT scans of the cervical spine without CVJ pathology were analyzed. These patients were referred from

various departments to radiology and the scan was taken. The majority of the patients (59) were a case of trauma. The full distribution of patients along with their categorical diagnosis is shown in Graph 1.

Patients with head and neck cancers got the CT done to see if there was any bony extension. Patients with spurs, deviated nasal septa, and other nasal complaints comprised the ear, nose, and throat category. Miscellaneous patients were considered so if the patient had deformities, a pathology fitting more than one category, or a pathology that would not fit any of the categories. Some patients who were being evaluated for headache had normal CTs. Vascular events included subarachnoid hemorrhage,

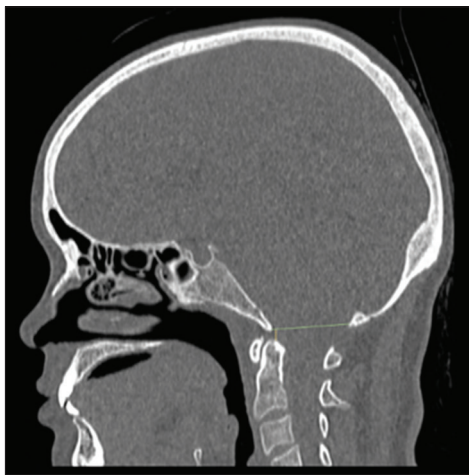

Figure 1: The distance between McRae's line and the odontoid process. The green line is representative of the McRae's line. The yellow line is representative of the distance between McRae's line and the tip of the odontoid process

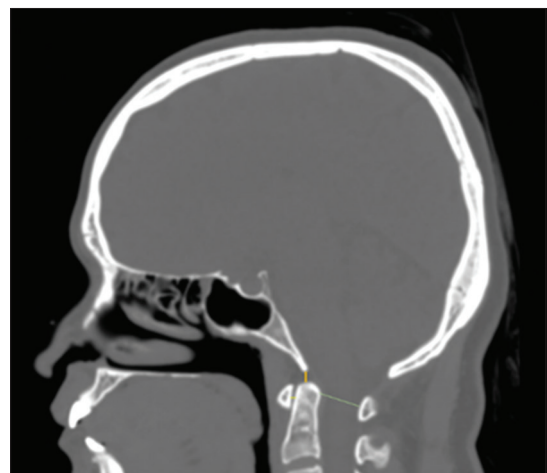


Figure 3: The anterior, posterior atlantodental interval, and basion-dens interval. The yellow line is representative of the anterior atlantodental interval. The green line is representative of the posterior atlantodental interval. The orange line shows the distance between the basion and dens (basion-dens interval)

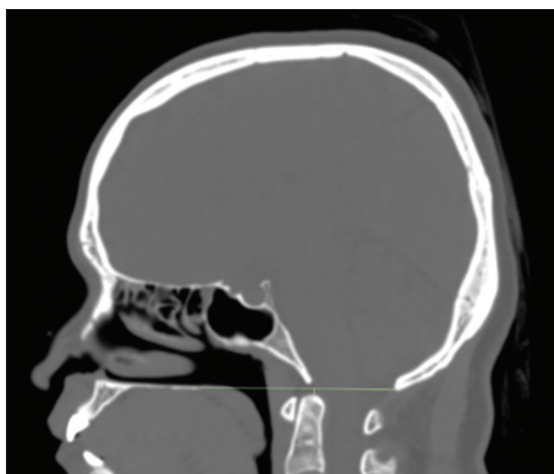


Figure 2: The distance between Chamberlain's line and the odontoid process. The green line is representative of the Chamberlain's line. The yellow line is representative of the distance between Chamberlain's line and the tip of the odontoid process. McGregor's line is considered to be a modification of the Chamberlain's line

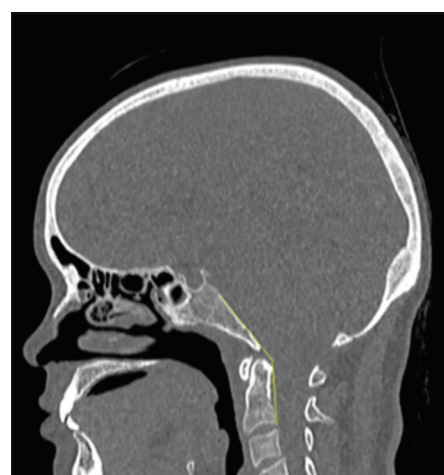


Figure 4: The clivus-canal angle. Although the angle has been defined differently by several authors, it can be simplified to the angle between two lines. One of which is drawn parallel to the posterior aspect of clivus and another of which is drawn connecting the superior-most and inferior-most points of the dorsal aspect of the odontoid process. The angle between the two joined yellow lines indicates the clivus-canal angle

hypertensive bleeds, and strokes. Few of the patients had CTs done postoperatively after undergoing spinal surgery. Some of the patients had independent findings of only

having neuroparenchymal atrophy and degenerative changes of the cervical spine. The patients with the degenerative changes still had a normal CVJ. Two patients had gotten a CT done in view of intracranial tumors.

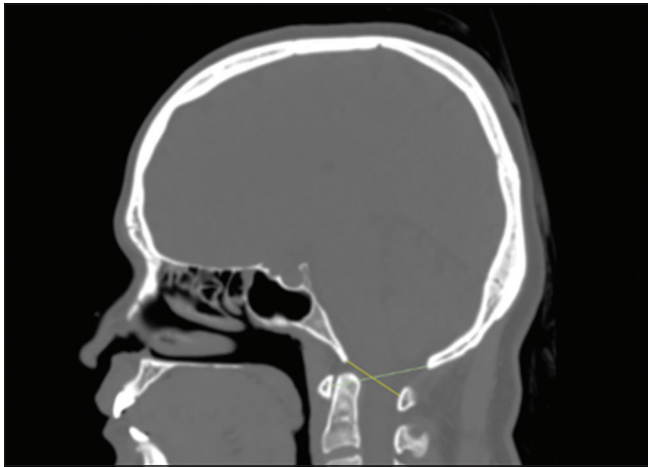
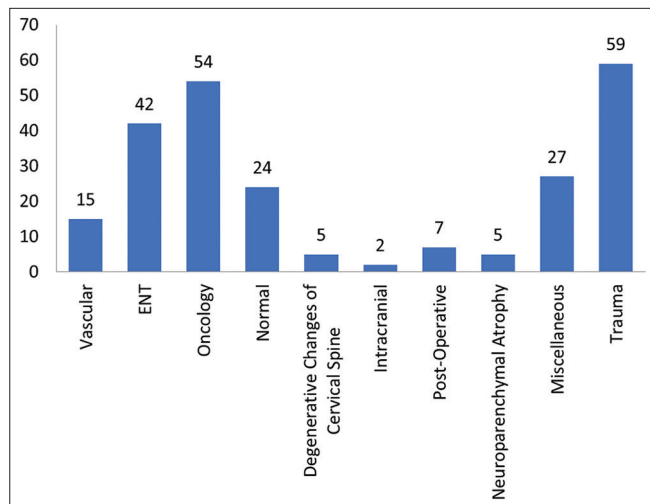


Figure 5: The two lines required to calculate the powers ratio. The yellow line extends from the basion to the posterior arch of the C1, whereas the green line extends from the opisthion to the anterior arch of the C1

The ages varied from 18 years to 84 years with a mean of 43.55 and standard deviation being 15.35. Out of the 240, there were 166 (69.2%) CTs belonging to males and 74 (30.8%) belonging to females. Table 1 shows the results from the present study. Wherever significance was looked into, $P < 0.05$ was considered to be significant.

Using the independent sample t-test, the differences among gender in the dMR parameter are identified and are shown in Table 2. $P = 0.320$ indicated that there was no significant difference between males and females.

Using the Mann–Whitney U-test, the differences among gender with the remaining parameters were identified and shown below in Table 3.



Graph 1: Distribution of patients and their diagnoses

A look into the significance of the parameters between the two sexes yielded $P = 0.001$ and 0.001 , respectively, for AADI and PADI. Males were more likely to have higher AADI and PADI values when compared to females. There was no significant differences between the two sexes when dMG, dCL, CCA, BDI, and PR were looked at ($P = 0.099, 0.168, 0.173, 0.798,$ and 0.069 , respectively). One sample t-test was done to compare the sample mean with the other studies.

DISCUSSION

The CVJ, aptly named, is the junction between the cranium and the cervical vertebrae. The foramen magnum, which serves as the intermediate between these two structures, allows for the passage of structures such as the brainstem, vertebral arteries, and the spinal root of the accessory nerve. Alteration of the normal anatomy

Table 1: Analysis from all CT scans

| Craniometric Parameters | Mean (mm) | Standard deviation (mm) | |
|-------------------------|--|-------------------------|--|
| AADI | 1.78 | 0.42 | |
| PADI | 18.12 | 1.97 | |
| dCL | -2.73 (average location of the tip of odontoid was found to be below the Chamberlain's line) | 2.63 | 203 (84.58%) CTs showed an odontoid tip below the Chamberlain's line. 37 (15.42%) CTs had an odontoid tip that was above this line |
| dMG | -2.29 (average location of the tip of odontoid was found to be below the McGregor line) | 2.79 | 191 (79.58%) CTs showed an odontoid tip below the McGregor line. 49 (20.42%) CTs had an odontoid tip above the line |
| dMR | -5.91 (average location of the tip of odontoid was below the McRae line) | 1.4 | No CT had an odontoid tip projecting above the McRae line |
| CCA | 160.82° | 7.14° | |
| BDI | 5.6 | 1.45 | |
| PR | 0.71 | 0.07 | |

AADI: Anterior atlantodental interval, PADI: Posterior atlantodental interval, dMG: Distance of tip of odontoid process to McGregor's line, dMR: Distance of tip of odontoid process to McRae's line, CCA: Clivus-canal angle, BDI: Basion dens interval, PR: Powers ratio

here can lead to grave consequences including mortality. Originally used to measure the intelligence of a race, craniometry has now evolved to recognize deviations from the normal, especially within in the CVJ. Ligament laxity and basilar invagination can be determined, along with other abnormalities when the normal ranges of the mentioned parameters have been exceeded. These measurements can also be used to create spinal implants meeting the exact needs of the patients.¹⁶ Due to its superiority in speed, precision, quality, and ability to focus on bony structures, CT has become the predominant imaging modality as opposed to standard radiography and magnetic resonance imaging.¹⁷ We hypothesize that different races will have different values and previously set standards cannot be applicable to all. Our 6 month – study yielded 240 CTs belonging to patients of Indian origin who had no CVJ abnormalities. These scans were performed for a variety of reasons of which mostly were due to trauma. Comparison of our results was then done with the previous literature, where details of the same and other races were highlighted to identify deviations among the races.

In previously performed studies using Indian patients, where sample sizes varied from 49 to 255,¹⁶⁻¹⁸ several of the same parameters (which include dMR, dCL, dMG, AADI, PADI, and CCA) were measured. These studies have noted the dMR to be 4.67 ± 1.69 ¹⁷ with another study noting the same measurement to be 5.11 ± 1.65 .¹⁶ We measured

a value of 5.91 ± 1.4 . Although creating an exact range may not be practical, simply determining if the odontoid exceeds or does not exceed that of the McRae's line should be satisfactory to define a regional pathology. Alike to the other studies, we also did not have a patient with an odontoid going beyond the McRae's line, and therefore, we conclude that using this line is the simplest method to detect abnormalities of the CVJ.

Marathe et al.,¹⁷ also looked at dMG and dCL. When they analyzed dMG, they have found a mean of 0.213 with minimum and maximum values of -6.065 and 7.237 , respectively. They have recorded a range of -7.865 – 6.237 with a mean of 0.498 when they looked into the dCL. Unlike our study, they have found a slight majority of patients to have an odontoid process above the two lines. In their analysis, 55.12% of the patients had the odontoid tip above the Chamberlain's line and 58.620% of the patients had the odontoid tip above the McGregor's line. In both parameters, our study has found an overwhelming majority of the odontoid tips to be below the lines. An odontoid tip above the Chamberlain's line may not be cause for concern since one-third of the normal population will have this finding as stated by McRae.¹²

The AADI, which measures the pre-dental space, is supported by the transverse ligament of the atlas, atlantodental ligament, and the alar ligament. An increased AADI can be an indication of transverse ligament rupture.¹⁸ The AADI measurement found in our study was 1.78 ± 0.42 . This value was higher than that found by Dash et al.,¹⁶ and that by Gupta et al.¹⁸ The PADI, in our study, was 18.12 ± 1.97 and this was also greater than the value found by Gupta et al.¹⁸ The PR is used to diagnose atlanto-occipital instability and if the value is greater than one, it is a sign that the patient has the mentioned abnormality. None of our patients had a ratio >1 and the same finding

Table 2: Statistical differences between genders in dMR

| Craniometric Parameters | Sex | N | Mean (mm) | Standard Deviation (mm) |
|-------------------------|-----|-----|-----------|-------------------------|
| dMR | M | 166 | -5.97 | 1.36 |
| | F | 74 | -5.78 | 1.48 |

dMR: Distance of tip of the odontoid process to McRae's line

Table 3: Statistical differences between genders in dMG, dCL, AADI, PADI, CCA, BDI, and PR

| Sex | dMG (mm) | dCL (mm) | AADI (mm) | PADI (mm) | CCA | BDI (mm) | PR |
|---------|----------|----------|-----------|-----------|---------|----------|-------|
| Male | | | | | | | |
| n | 166 | 166 | 166 | 166 | 166 | 166 | 166 |
| Median | -2.545 | -2.850 | 1.810 | 18.150 | 158.900 | 5.730 | 0.699 |
| Minimum | -9.420 | -9.220 | 0.771 | 14.300 | 150.000 | 1.850 | 0.543 |
| Maximum | 4.130 | 4.470 | 2.990 | 24.700 | 178.910 | 8.410 | 0.878 |
| Mean | -2.500 | -2.888 | 1.846 | 18.419 | 160.425 | 5.624 | 0.703 |
| SD | 2.765 | 2.584 | 0.421 | 2.001 | 7.130 | 1.400 | 0.068 |
| Female | | | | | | | |
| n | 74 | 74 | 74 | 74 | 74 | 74 | 74 |
| Median | -2.110 | -2.715 | 1.640 | 17.150 | 161.300 | 5.550 | 0.714 |
| Minimum | -7.280 | -8.160 | 0.924 | 14.400 | 150.300 | 1.870 | 0.604 |
| Maximum | 4.230 | 3.710 | 2.800 | 21.600 | 176.680 | 8.470 | 0.960 |
| Mean | -1.817 | -2.384 | 1.633 | 17.435 | 161.708 | 5.561 | 0.722 |
| SD | 2.802 | 2.709 | 0.396 | 1.725 | 7.121 | 1.577 | 0.065 |

AADI: Anterior atlantodental interval, PADI: Posterior atlantodental interval, dMG: Distance of tip of odontoid process to McGregor's line, CCA: Clivus-canal angle, BDI: Basion dens interval, PR: Powers ratio, dCL: Distance of tip of odontoid process to Chamberlain's line

Table 4: Comparison of craniometric parameters between different races

| Race as mentioned by previous studies | dMR (mm) | dMG (mm) | dCL (mm) | CCA | AAI (mm) | PADI (mm) | BDI (mm) | PR |
|--|--|--|--|------------------------|--|--------------------|-------------------|-------------------|
| Indian—Present Study | -5.91±1.4 | -2.29±2.79 | -2.73±2.63 | 160.82°±7.14° | 1.76±0.42 | 18.12±1.97 | 5.60±1.45 | 0.71±0.07 |
| Indian—Dash et al. ¹⁶ | 5.11±1.65 (all below the line) P=0.001 | | | 150.69°±12.05° P=0.001 | 1.12±0.66 P=0.001 | | | |
| Indian—Marathe et al. ¹⁷ | 4.6±1.69 (all below the line) P=0.001 | 0.213 (mean) P=0.001 | 0.498 (mean) P=0.001 | | | | | |
| Indian—Gupta et al. ¹⁸ | | | | | 1.3±0.43 P=0.001 | 16.77±2.08 P=0.001 | | |
| Turkish—Ozdoğan et al. ⁵ | | | | | Male: 1.47±0.29 P=0.001 Female: 1.51±0.25 P=0.009 | | | |
| South East Anatolian—Tanrisever et al. ¹⁹ | 5.30±1.59 (all below the line) p=0.001 | 0.31±3.22 (values both crossed and did not cross the line) P=0.001 | 1.06±3.22 (values both crossed and did not cross the line) P=0.001 | 157.62°±11.85° P=0.001 | 1.28±0.48 P=0.001 | 19.54±2.24 P=0.001 | 4.92±1.77 P=0.001 | 0.72±0.06 P=0.013 |
| UK—Kwong et al. ²² | 5.8±1.6 (all below the line) P=0.001 | 1.6±2.8 (values both crossed and did not cross the line) P=0.001 | 2.3±2.6 (values both crossed and did not cross the line) P=0.001 | | | | | |
| Brazilian—Batista et al. ¹³ | | | 1.5±2.2 (values both crossed and did not cross the line) P=0.001 | 153.6°±7.6° P=0.001 | 1.1±0.3 P=0.001 | | | |
| Chinese—Chen Y et al. ²¹ | | | | | Male: 1.83±0.46 P=0.634 Female: 1.63±0.43 P=0.943 | | | |

The P values mentioned below were determined using a one sample t-test. They represent significant differences found when comparing the metrics of our study to the metrics of the other studies, AAI: Anterior atlanto-dental interval, PADI: Posterior atlanto-dental interval, dCL: Distance of tip of the odontoid process to Chamberlain's line, dMG: Distance of tip of the odontoid process to McGregor's line, CCA: Clivus-canal angle, BDI: Basion-dens interval, PR: Powers ratio

was also seen in the study done by Tanrisever et al.¹⁹ Alike to the PR, the BDI is also used to identify atlanto-occipital instability, particularly sublaxations, and dislocations. Apart from atlanto-occipital distractions, deviations from the normal measurement may also be seen in rheumatoid arthritis as well as congenital deformities of the upper cervical vertebrae.¹⁹ The BDI found in the present study is 5.60 ± 1.45 . In the study done by Tanrisever et al., they found a BDI of 4.92 ± 1.77 .¹⁹

The CCA value in our study was 160.82 ± 7.14 . Dash et al., found their value to be $150.69^\circ \pm 12.05^\circ$.¹⁶ In the same report, they had CCA values range from 118.20° to 173.70° .¹⁶ Although our study did not have values below 150° , this invites further examination into what is considered a normal CCA. This value is subject to difference as head posture can cause changes in the recordings.²⁰ Too narrow an angle can cause brainstem compression.¹⁹

We also compared CVJ studies performed on the Turkish, South East Anatolian, UK, Brazilian, and Chinese population with ours. Among these studies, two of them specifically analyzed AADI in males and females and we also compared those results with ours.^{5,21} Table 4 shows a compilation of the values mentioned in the literature compared to our values.

Overall, our values were higher for all the parameters and were more likely to be further away from the lines when compared to what the other authors have found. Exceptions to this were found in the study by Tanrisever et al.,¹⁹ where we found lower PADIs and PRs when compared to their findings, and the study by Chen et al.,²¹ where we found our mean values for AADI in females to be the same. The varying ranges in values may be attributed to the cultural practices of the different races and possibly even the socioeconomic status.¹⁸ Although male-female difference was found to be significant in the AADI and PADI parameters in the present study, seldom was any such difference recorded in the other studies.^{5,13,16-19,21,22} Similar to our study, Gupta et al., and Tanrisever et al., also found a significant difference between males and females when PADI was scrutinized (males had higher values).^{18,19} Chen et al., found a statistical significance between males and females when AADI was examined (males had higher values).²¹ Alike to the findings of Dash et al., and Marathe et al., our study also showed no differences between genders when examining dMR, dMG, dCL, and CCA.^{16,17}

After analyzing the data and comparing our results with that of the other races, we conclude that the data mentioned in the literature are not on par with what was observed in the present study. Although the values varied within the

normal range, achieving nil statistical significance between the same and other populations may prove challenging. Our comparison to other races should not be regarded as a doctrine that must be followed, but rather it should be considered as an introduction to creating a broader platform where all races and respective craniometric values can be displayed and utilized in neurosurgical practice.

Limitations of the study

Limitations to the study include the lack of access to the patient and lack of standardization in the retrospective study. Doing so and having control of the patient when they visit the radiology department could have helped standardize the head posture, while the CT was being done. Access to the patient to elicit a quick history of clinical CVJ incompetence would have also helped create correlations with the radiological findings.

CONCLUSION

Due to the consistent finding of the odontoid tip being below the McRae's line among the races examined, we would like to agree with the existing literature that this parameter is the easiest to utilize to reliably differentiate a CT with and without CVJ pathology. Further investigation will be required to outline the other values. Creating fixed ranges for parameters will be difficult due to both intra- and inter-population variability. To overcome this challenge, a large-scale database has to be created with measurements of multiple, if not all, races. Only then can we understand the limits of a normal CVJ and subsequently craft individualized instruments and prostheses for each patient's needs.

ACKNOWLEDGMENT

We would like to thank Dr. Mariamma Philip who is an additional professor in the Department of Biostatistics at the National Institute of Mental Health and Neurosciences, Bangalore, India. Dr. Philip has provided valuable aid in the statistical analysis.

REFERENCES

1. Harris J Jr. The cervicocranium: Its radiographic assessment. *Radiology*. 2001;218(2):337-351. <https://doi.org/10.1148/radiology.218.2.r01fe53337>
2. Chandra PS, Kumar A, Chauhan A, Ansari A, Mishra NK and Sharma BS. Distraction, compression, and extension reduction of basilar invagination and atlantoaxial dislocation: A novel pilot technique. *Neurosurgery*. 2013;72(6):1040-1053. <https://doi.org/10.1227/NEU.0b013e31828bf342>
3. Goel A and Shah A. Atlantoaxial joint distraction as a treatment for basilar invagination: A report of an experience with 11 cases.

- Neurol India. 2008;56(2):144150.
<https://doi.org/10.4103/0028-3886.41991>
4. Goel A. Is atlantoaxial instability the cause of Chiari malformation? Outcome analysis of 65 patients treated by atlantoaxial fixation. *J Neurosurg Spine*. 2015;22(2):116127.
<https://doi.org/10.3171/2014.10.SPINE14176>
 5. Ozdoğan S, Köken M, Gergin YE, Aydın YO, Yüce E and Tiryaki M. Measurement of anterior atlantodental interval in adults with computerized tomography. *J Turk Spinal Surg*. 2014;25:193-197.
 6. Jain N, Verma R, Garga UC, Baruah BP, Jain SK and Bhaskar SN. CT and MR imaging of odontoid abnormalities: A pictorial review. *Indian J Radiol Imaging*. 2016;26(1):108-119.
<https://doi.org/10.4103/0971-3026.178358>
 7. Boden SD, Dodge LD, Bohlman HH and Rehtine GR. Rheumatoid arthritis of the cervical spine. A long-term analysis with predictors of paralysis and recovery. *J Bone Joint Surg Am*. 1993;75(9):1282-1297.
<https://doi.org/10.2106/00004623-199309000-00004>
 8. Greenberg MS. Other Non-Spine Conditions with Spine Implications. *Handbook of Neurosurgery*. 9th ed. New York, Rio De Janeiro: Thieme; 2020. p. 1195. Available from: <https://www.thieme.com/books-main/neurology/product/5411-handbook-of-neurosurgery> [Last accessed on 2022 July 20]
 9. Chamberlain WE. Basilar impression (platybasia): A bizarre developmental anomaly of the occipital bone and upper cervical spine with striking and misleading neurologic manifestations. *Yale J Biol Med*. 1939;11(5):487-496.
 10. Traughber B, Hodak J, Mamourian A, Coffey M and Hsu D. In: Bambakidis NC, Dickman CA, Spetzler RF and Sonntag VK editors. *Radiological Evaluation of the Craniovertebral Junction. Surgery of the Craniovertebral Junction*. 2nd ed. New York: Thieme; 2013. p. 64.
<https://doi.org/10.1007/s00701-012-1546-3>
 11. McGreger M. The significance of certain measurements of the skull in the diagnosis of basilar impression. *Br J Radiol*. 1948;21(244):171181.
<https://doi.org/10.1259/0007-1285-21-244-171>
 12. McRae DL and Barnum AS. Occipitalization of the atlas. *Am J Roentgenol Radium Ther Nucl Med*. 1953;70(1):2346.
 13. Batista UC, Joaquim AF, Fernandes YB, Mathias RN, Ghizoni E and Tedeschi H. Computed tomography evaluation of the normal craniocervical junction craniometry in 100 asymptomatic patients. *Neurosurg Focus*. 2015;38(4):E5.
<https://doi.org/10.3171/2015.1.FOCUS14642>
 14. Smoker WR. Craniovertebral junction: Normal anatomy, craniometry, and congenital anomalies. *Radiographics*. 1994;14(2):255-277.
<https://doi.org/10.1148/radiographics.14.2.8190952>
 15. Ross JS and Moore KR. *Measurement Techniques. Diagnostic Imaging: Spine*. 3rd ed. Philadelphia, PA: Elsevier; 2015. p. 11. Available from: <https://www.us.elsevierhealth.com/diagnostic-imaging-spine-9780323793995.html> [Last accessed on 2022 July 20]
 16. Dash C, Singla R, Agarwal M, Kumar A, Kumar H, Mishra S, et al. Craniovertebral junction evaluation by computed tomography in asymptomatic individuals in the Indian population. *Neurol India*. 2018;66(3):797-803.
<https://doi.org/10.4103/0028-3886.232288>
 17. Marathe NA, Dahapute AA, Desai JR, Dhole KP, Bhaladhare S and Shah S. X-ray and computed tomography scan-based morphometric analysis of skull baselines in Indian population. *Asian J Neurosurg*. 2019;14(4):1116-1121.
https://doi.org/10.4103/ajns.AJNS_201_19
 18. Gupta PP, Dhok AM, Shaikh ST, Patil AS, Gupta D and Jagdhane NN. Computed tomography evaluation of craniovertebral junction in asymptomatic central rural Indian population. *J Neurosci Rural Pract*. 2020;11(3):442-447.
<https://doi.org/10.1055/s-0040-1712719>
 19. Tanrisever S, Orhan M, Bahşi İ and Yalçın ED. Anatomical evaluation of the craniovertebral junction on cone-beam computed tomography images. *Surg Radiol Anat*. 2020;42(7):797-815.
<https://doi.org/10.1007/s00276-020-02457-z>
 20. Nascimento JJ, Neto EJ, Mello-Junior CF, Valença MM, Araújo-Neto SA and Diniz PR. Diagnostic accuracy of classical radiological measurements for basilar invagination of Type B at MRI. *Eur Spine J*. 2019;28(2):345-352.
<https://doi.org/10.1007/s00586-018-5841-4>
 21. Chen Y, Zhuang Z, Qi W, Yang H, Chen Z, Wang X, et al. A three-dimensional study of the atlantodental interval in a normal Chinese population using reformatted computed tomography. *Surg Radiol Anat*. 2011;33(9):801-806.
<https://doi.org/10.1007/s00276-011-0817-7>
 22. Kwong Y, Rao N and Latief K. Craniometric measurements in the assessment of craniovertebral settling: Are they still relevant in the age of cross-sectional imaging? *AJR Am J Roentgenol*. 2011;196(4):W421-W425.
<https://doi.org/10.2214/AJR.10.5339>

Authors Contribution:

SBV- Conceptualization, Methodology, Investigation, Data curation, Writing - Original Draft, Writing – review and editing; **RSL**- Investigation, Writing - Original Draft, Writing – review and editing; **MSB**- Conceptualization, Methodology, Investigation, Data curation, Writing - Original Draft, Writing – review and editing; **SH**- Writing – review and editing; **AK**- Writing – review and editing; **HS**- Writing – review and editing.

Work attributed to:

Vydehi Institute of Medical Sciences and Research Centre, EPIP Zone, Whitefield, Bengaluru - 560 066, Karnataka, India.

Orcid ID:

Sandeep BV - <https://orcid.org/0000-0003-4248-9062>
 Raj Swaroop Lavadi - <https://orcid.org/0000-0002-2801-6472>
 Manpreet Singh Banga - <https://orcid.org/0000-0001-9102-9041>
 Sangamesh Halhalli - <https://orcid.org/0000-0003-3278-5925>
 Anantha Kishan - <https://orcid.org/0000-0002-5778-1579>
 Hiba Salam - <https://orcid.org/0000-0001-8278-3085>

Source of Support: Nil, **Conflict of Interest:** None declared.