

Hashimoto's thyroiditis presenting as cerebellar stroke



Robin George Manappallil

Robin George Manappallil, Consultant, Physician, Department of Medicine, National Hospital, Calicut, Kerala, India

Submitted: 01-02-2016

Revised: 23-02-2016

Published: 01-07-2016

ABSTRACT

Hashimoto's thyroiditis (HT) or autoimmune hypothyroidism is the most common form of primary hypothyroidism, characterized by lymphocytic infiltration of the thyroid gland thereby leading to its destruction. It is more common in females. Genetic factors and chronic exposure to high iodine diet also play an important role. Hypertension, in these patients, is the result of increased peripheral resistance and arterial stiffness. The patient being reported is a 54 year old female with uncontrolled hypertension who presented with cerebellar infarct and was diagnosed to have HT. Following therapy with levothyroxine, her blood pressure was well controlled. This case emphasises the need for thyroid evaluation in all patients with uncontrolled hypertension.

Key words: Hashimoto's thyroiditis, Hypothyroidism, Hypertension, Stroke

Access this article online

Website:

<http://nepjol.info/index.php/AJMS>

DOI: 10.3126/ajms.v7i4.14505

E-ISSN: 2091-0576

P-ISSN: 2467-9100

INTRODUCTION

Hashimoto's thyroiditis, also known as chronic lymphocytic thyroiditis, is one of the commonest cause of primary hypothyroidism where the immune system attacks the thyroid gland, leading to its destruction. Peripheral vascular resistance and arterial stiffness are the causes of hypertension in these patients. Hypertension itself is a risk factor for ischemic stroke because of its damaging effect on blood vessels. Hypothyroid patients have hypercholesterolemia, thereby leading to atherosclerosis and increase risk of stroke. The patient being reported is a case of uncontrolled hypertension, presenting as cerebellar stroke and was diagnosed to have an underlying HT. On initiation of levothyroxine, her blood pressure was well controlled, suggesting the treatment of hypothyroidism as a modifiable risk factor for hypertension and stroke.

CASE REPORT

A 54 year old married lady, homemaker, presented to emergency department with complaints of giddiness and headache since 3 days which was insidious in onset and progressive in nature. There was no postural variation. She also complained of fatigue and forgetfulness. There

were no other associated or other systemic complaints. She is a hypertensive for the past 10 years on regular medications (Telmisartan 80 mg o.d. + Amlodipine 5 mg b.d. + Metoprolol 25 mg b.d.) but her blood pressure always remained between 150 to 170 mmHg systolic and 100 to 110 mmHg diastolic (as per the BP charting maintained by her). She is not a known case of diabetes or ischemic heart disease. She is not on any other medications. She has two children, born of normal vaginal delivery, and there was no history of abortion or preeclampsia.

On examination, she was conscious, oriented and afebrile. Her pulse rate was 60 beats/minute which were regular, blood pressure of 200/110 mmHg, and respiratory rate of 20 breaths/minute with oxygen saturation 96% (room air). Her neurological examination revealed positive cerebellar signs on the left i.e. ataxia, finger nose test, knee heel in coordination, dysdiadochokinesis and tandem walking. Other systemic examinations were normal.

Her MRI Brain showed infarct in left cerebellum (Figures 1, 2). Neck vessel doppler was normal. Her complete blood count showed mild anaemia with Hb 12 gm%. Peripheral smear showed microcytic hypochromic picture. Her renal functions, electrolytes and liver functions

Address for correspondence:

Robin George Manappallil, Consultant, Physician, Department of Medicine, National Hospital, Calicut, Kerala - 673009, India.

Tel: 0091-8547753396, **E-mail:** drrobingorgeempl@gmail.com

© Copyright AJMS

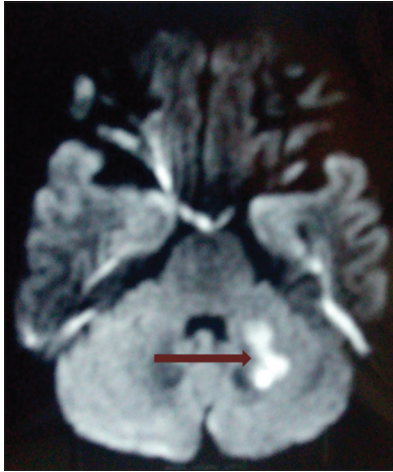


Figure 1: DWI image showing restricted diffusion in left cerebellar hemisphere suggestive of infarct

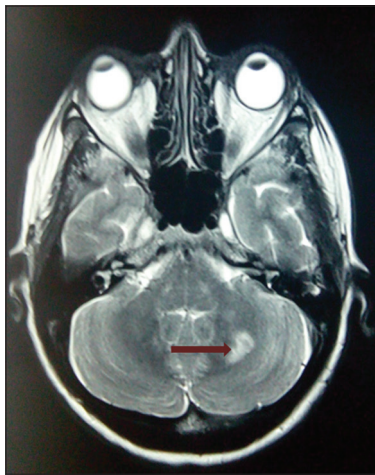


Figure 2: T2W image showing a focal hyperintensity in left cerebellar hemisphere suggestive of infarct

were normal. Her ECG and chest X-ray were normal and ECHO heart showed mild left ventricular hypertrophy. As per her history of fatigue and poor memory, her thyroid profile was checked, which showed TSH 141.23 (0.4 – 4 μ IU/ml), T3 < 25 (60 – 180 ng%) and T4 < 1 (5 – 11.5 μ g%). Her antibody to thyroid peroxidase was positive, suggestive of HT. ANA and anti dsDNA were negative and homocysteine levels were normal. Her fasting lipid profile revealed hypercholesterolemia with LDL 170, VLDL 35, HDL 45 and triglycerides 250. Her fasting and post prandial sugars and HbA1c were normal.

Patient was started on antiplatelets and statins. Her blood pressure was controlled with Telmisartan 40 mg. She was started on 75 μ g levothyroxine. She was discharged after 1 week, once she became symptomatically better and was advised weekly follow up.

After 1 month of therapy with levothyroxine, patient became symptomatically better. Her blood pressure was

well controlled with Telmisartan 40 mg o.d. compared to the triple drug therapy she was taking earlier. Her thyroid profile also started showing improvement.

DISCUSSION

HT is a form of autoimmune hypothyroidism which presents with goiter. The condition is more common in women and the mean age at the time of diagnosis is 60 years. It is characterized by marked lymphocytic infiltration, composed of CD4+, CD8+ and B cells, of the gland with germinal cell formation. It is accompanied by atrophy of the thyroid follicle, absence of colloid, oxyphil metaplasia and fibrosis. Antibodies to thyroid peroxidase (TPO) and thyroglobulin (Tg) are useful markers for determining thyroid autoimmunity.¹

Some of the common symptoms of hypothyroidism include fatigue, dry skin, hair loss, weight gain with decreased appetite, menstrual irregularities and poor memory. Patients with HT may present with goiter which is usually irregular and firm in consistency. Hypertension, mainly diastolic, in these patients is the result of increased peripheral vascular resistance.¹ Hypothyroid patients also show alterations in autonomic nervous system i.e. increase in plasma norepinephrine concentration.² There is also reduced dopaminergic activity in the central nervous system due increase in prolactin and TSH concentration.^{3,4} High levels of TSH have been demonstrated in hypertensive patients and adequate thyroid hormone replacement therapy has been proved to be effective in reducing blood pressure in them.^{5,6} Atherosclerosis has been linked with hypothyroidism.⁷ Hypothyroid patients are subject to hypercholesterolemia, with marked increase in LDL levels.⁸ Moreover, endothelial dysfunction is present in hypothyroidism, which may be the initiating event in atherosclerosis.⁹

The risk of stroke is increased in hypothyroid patients either as a result of atherosclerosis or due to hypertension. Moreover, hypertension alone is a risk factor for stroke. This case report emphasises the need to consider and treat HT in all cases of hypertension, especially uncontrolled, and stroke.

REFERENCES

1. Jameson JL, Mandel SJ and Weetman AP. Disorders of the thyroid gland. In: Kasper, Fauci, Hauser, Longo, Jameson, Loscalzo eds. Harrison's principles of internal medicine. 19th ed. McGraw Hill education 2015, 2289-2293.
2. Coulombe P, Dussault JH and Walker P. Plasma catecholamine concentrations in hyperthyroidism and hypothyroidism. *Metabolism* 1976;25: 973.

3. Fcek CM, Sawers JSA, Brown NS, Seth J, Irvine SW and Toft AD. Influence of thyroid status on dopaminergic inhibition of thyrotropin and prolactin secretion. Evidence for an additional feedback mechanism in the control of thyroid hormone secretion J Clin Endocrinol Metab 1980; 51: 585.
4. Snyder PJ, Jacobs LS, Utiger RD and Daughaday WH. Thyroid hormone inhibition of the prolactin response to thyrotropin releasing hormone. J Clin Invest 1973; 52: 2324.
5. Omae T, Ueda K, Nakashima T and Inoue K. Latent hypothyroidism as a possible cause of hypertension? Abstract of eighth scientific meeting of the International Society of Hypertension. Milan. 1981. p 166.
6. Saito I, Ito K and Saruta T. Hypothyroidism as a cause of hypertension. Hypertension. 1983;5(1):112-115.
7. Cappola AR and Ladenson PW. Hypothyroidism and atherosclerosis. J Clin Endocrinol Metab 2003;2438-2344.
8. Duntas LH. Thyroid disease and lipids. Thyroid 2002;12:287-293.
9. Lekakis J, Papamichael C, Alevizaki M, Pipingos G, Marafelia P, Mantzos J, et al. Flow-mediated, endothelium- dependent vasodilation is impaired in subjects with hypothyroidism, borderline hypothyroidism and high-normal thyrotropin (TSH) values. Thyroid 1997;7:411-414.

Author Contribution:

RGM - Treating physician, author and corresponding author.

Source of Support: Nil. **Conflict of Interest:** None.