

# Capnography-assisted airway management by awake blind nasal intubation in maxillofacial surgeries: An observational study



Minal Kokate<sup>1</sup>, Vikram Kokate<sup>2</sup>, Gaurav Dubey<sup>3</sup>, Vijaya Borkar<sup>4</sup>

<sup>1</sup>Assistant Professor, <sup>4</sup>Professor, Department of Anesthesiology, <sup>2</sup>Associate Professor, Department of Emergency Medicine, <sup>3</sup>Associate Professor, Department of Respiratory Medicine, Dr. Panjabrao Deshmukh Memorial Medical College and Hospital, Amravati, Maharashtra, India

Submission: 17-10-2023

Revision: 29-01-2024

Publication: 01-03-2024

## ABSTRACT

**Background:** Maxillofacial surgery patients frequently pose challenges to airway management due to anatomical and functional constraints. While fiber-optic-aided nasotracheal intubation is considered the gold standard, not all medical facilities have access to fiber-optic bronchoscopes, particularly in low-resource settings. In such situations, awake nasal tracheal intubation is often the safest approach for managing patients with known or suspected difficult airways. **Aims and Objectives:** (1) To assess the technique of capnography-assisted airway management by awake blind nasal intubation (ABNI) in maxillofacial surgeries. (2) To find out any complications encountered by the technique of capnography-assisted airway management by ABNI in maxillofacial surgeries. **Materials and Methods:** 40 patients undergoing various maxillofacial surgeries and in whom blind nasotracheal intubation was attempted were included in this study. The institutional ethical committee approved the study, and informed consent was obtained from all the patients. The number of attempts for ABNI, successful versus failed ABNI, and complications encountered were studied. SSPS 21.0 software was used for statistical analysis. **Results:** There were 23 (57.50%) males and 17 (42.50%) females. There was a male preponderance, with the M: F ratio being 1:0.73. The mean age of the patients was  $40.97 \pm 8.92$  years. In 36 (90%) of the patients, the intubation could be successfully done. In 19 (47.50%) patients, blind nasal intubation was successfully done in the first attempt; 2 attempts were required in 15 (37.50%) patients, and 3 attempts were required in 2 (5%) patients. Epistaxis (10%) and sore throats (7.5%) were the most common complications in the studied cases. **Conclusion:** Capnography-assisted ABNI is an effective technique for airway control in patients undergoing maxillofacial surgeries with an acceptable complication rate.

**Key words:** Maxillofacial surgeries; Nasal intubation; Capnography; Epistaxis

### Access this article online

**Website:**

<http://nepjol.info/index.php/AJMS>

**DOI:** 10.3126/ajms.v15i3.59348

**E-ISSN:** 2091-0576

**P-ISSN:** 2467-9100

Copyright (c) 2024 Asian Journal of Medical Sciences



This work is licensed under a Creative Commons Attribution-NonCommercial 4.0 International License.

## INTRODUCTION

Patients presenting for maxillofacial surgeries are known to have difficult airway assessments due to their anatomical and functional restrictions. Fiberoptic-aided nasotracheal intubation is taken as the “gold standard” to secure the airway in patients for maxillofacial surgery.<sup>1</sup> The intubating options for these patients are few and difficult and consist of blind nasal intubation, video laryngoscope, fiber-optic bronchoscope (FOB)-assisted intubation, retrograde intubation, and tracheostomy. Not every institute has a

fiber-optic bronchoscope, especially in low-resource setups, so an alternative method should be considered. Awake nasal tracheal intubation is often the safest way to manage patients with known or suspected difficult airways. The nasal intubation technique was first described in 1902 by Kuhn. The other pioneers of nasal intubation techniques were MacEwen, Rosenberg, Meltzer, Auer, and Elsberg.<sup>2</sup>

During World War I, Rowbotham and Magill developed and practiced the technique of “blind” nasal intubation and coined the term. It was popularized by Magill in the 1920s.

### Address for Correspondence:

Dr. Minal Kokate, Assistant Professor, Department of Anesthesiology, Dr. Panjabrao Deshmukh Memorial Medical College and Hospital, Amravati, Maharashtra, India. **Mobile:** +91-9167271783. **E-mail:** dr.minal2004@gmail.com

Most commonly, this technique is employed in the operating room for dental procedures, intraoral (e.g., mandibular reconstructive procedures or mandibular osteotomies), oropharyngeal surgeries, maxillofacial surgeries, and patients with limited mouth openings (e.g., trismus).<sup>3</sup> For patients with difficult or impossible tracheal intubation, awake blind nasal intubation (ABNI) has become an accepted method for securing an airway. It usually does not require the availability of a special device. Despite the multitude of available airway management techniques, it remains a helpful alternative to difficult airway management and can be a lifesaving technique in emergencies. Nasotracheal intubation involves the tracheal tube pass through the nose, thereby allowing better isolation and good surgical access for intraoral procedures. One must know the anatomy involved, the pathway and procedure of intubation, the pre-anesthetic medication, and any complications that may be seen at the time of intubation.<sup>4</sup>

An informed and reassured patient adds to the success of awake intubation. Modern short-acting analgesics and amnesiacs are excellent for this purpose, and they have improved the use of this technique by providing conscious sedation and maintaining spontaneous ventilation. ABNI has been long recognized as relatively easy in spontaneously breathing patients, and success rates ranging from 72% to 86% have been reported.<sup>5</sup> In a difficult airway scenario, when combined with topical anesthesia of the nasal passages, superior laryngeal nerve block, transtracheal block, and appropriate decongestion of the airway, it is probably the safest and easiest technique.<sup>6</sup> However, its use has since declined because it is a blind procedure that needs more time than the better alternatives that came on the scene, like flexible fiberoptic-guided techniques. All this led to a lack of appropriately skilled and trained personnel, bringing it further down in the preference order. It is believed that even in well-equipped tertiary centers with personnel trained in the use of fiberoptic scopes, there can be areas and situations where the attending airway manager might be bailed out by the skill of BNTI. Hence, it becomes imperative that young trainees be appropriately exposed to this “fading” art, thereby adding a useful skill to their repertoire.

Continuous capnography recordings were made during ABNI in patients breathing spontaneously. In addition to the auscultatory findings, capnography gives valuable information about the position of the endotracheal tube during the entire intubation procedure. The low and peaked CO<sub>2</sub> waves recorded from the nasopharynx tended to become higher and more flat-topped as the larynx was approached. If the tip of the endotracheal tube erroneously glides behind the larynx, it can be recognized by the absence of CO<sub>2</sub> in the recording.<sup>7</sup> On the other hand, the entrance of the tube

into the trachea could always be rapidly detected, as were the typical flat-topped CO<sub>2</sub> waves seen in the capnogram. Thus, capnography facilitates orientation during ABNI and rapidly detects accidental oesophageal intubation. The capnographic recording is also a valuable and reliable additional sign and document of correct endotracheal intubation. In adult and pediatric practice, capnography is widely used to confirm successful endotracheal tube placement and monitor ventilation. Moreover, investigators have modified the original ABNI that “went by the ear” by adding features that make ABNI “less blind.” Cuff inflation, lighted stylets, Beck airflow airway monitor whistles, endotracheal tubes and whistle combinations, and end-tidal carbon dioxide (EtCO<sub>2</sub>) monitoring are some such additions.<sup>8</sup>

We conducted this observational study to assess the technique of capnography-assisted airway management by ABNI in maxillofacial surgeries.

### Aims and objectives

1. To assess the technique of capnography assisted airway management by awake blind nasal intubation in maxillofacial surgeries.
2. To find out complications encountered by the technique of capnography assisted airway management by awake blind nasal intubation in maxillofacial surgeries.

## MATERIALS AND METHODS

This was an observational study in which 40 patients undergoing various maxillofacial surgeries and for whom ABNI was attempted were included on the basis of pre-defined inclusion and exclusion criteria. The study was conducted in the department of anesthesiology of Dr. Panjabrao Deshmukh Memorial Medical College, Amravati, Maharashtra. The institutional ethical committee approved the study, and informed written consent was obtained from all the patients. Using OPENEPI software version 3 based on data from this institute, which showed that last year, approximately 5% of surgeries were maxillofacial surgeries, assuming 90% power and a 95% confidence interval, the minimum sample size required was 37 patients. Based on the central limit theorem, the sample size was determined to be enough if it was more than 37; thus, we included 40 patients in this study.

On the pre-operative anesthesia visit, patients were examined for the airway assessment with a standard pro forma, which included previous anesthetic problems, general appearance of the face, neck, maxilla, and mandible, jaw movement, head extension and movement, teeth and oropharynx, nasal obstruction or deviated nasal septum, soft tissues of the neck, thyroid enlargement, findings of the recent chest and cervical spine radiographs, and any gross anatomical

distortion. Patients were also assessed for spontaneous ventilatory exchange and an intact cough reflex. The difficulty of intubation was assessed and recorded.

#### Awake blind intubation procedure

Each patient was pre-medicated with injection of glycopyrrolate 0.2 mg IM and injection Ondansetron 4 mg IV, was given 15 min prior to the procedure. Intravenous access was established. A 20 G cannula-ringer lactate infusion was started. The pharyngeal mucosa was sprayed with 10% lignocaine spray. Two drops of xylometazoline nasal drops were put into the nares after checking the patency of nares. Bilateral superior laryngeal nerve block with 2% xylocaine with adrenaline (1 cc each side) and transtracheal block by injecting 2 cc of 2% xylocaine with adrenaline by puncturing at the cricothyroid membrane were done. Injection midazolam 1 mg and injection fentanyl 50 mcg were given IV slowly. Supplementary sedatives were gradually titrated according to the anesthesiologist until a Ramsay score of 3 for sedation was achieved. The patient was pre-oxygenated with a facemask. The patient's head and neck, if not contraindicated, were placed in the sniffing position. A well-lubricated (with lignocaine jelly 2%) nasopharyngeal airway was then gently introduced to test the patency of the nasal passage and provide additional topical anesthesia. By replacing the nasal airway, the lubricated north pole portex RAE endotracheal tube was connected with a side-stream EtCO<sub>2</sub> connector at the machine end of The tube was passed along the floor of the nose beneath the inferior turbinate. The tube was assessed in relation to the trachea by looking for a visible bulge in the anterior neck or by listening to the breath sounds. The tube was advanced into the trachea through the glottis, guided by breath sounds and an EtCO<sub>2</sub> graph. If unsuccessful, the patient's head was repositioned, and the tube was facilitated through optimal external laryngeal manipulation to improve the anterior-posterior relationship of the tube to the trachea. The head was flexed if needed. The patient was then asked to take rapid, deep breaths so that intubation could be accomplished during inhalation or exhalation.

During the entire period of the tube manipulation, breath sounds were observed, and when the highest intensity of breath sounds was heard, the nasotracheal tube was advanced rapidly until it reached the trachea. Successful intubation was frequently followed by coughing, but the only reliable indication was the visual observation of gas exchange through the reservoir bag and verification of B/L equal pulmonary breath sounds with a stethoscope. The position of the tube was confirmed with capnography, and the cuff was inflated. Propofol 2 mg/kg and injection atracurium 0.5 mg/kg intravenously were administered to induce general anesthesia and establish mechanical ventilation, and the surgery was allowed to proceed.

The outcome was assessed in terms of total successful nasotracheal intubations, and number of attempts required, mean time for intubation, intraoperative and post-operative complications, if any. SPSS 21.0 was used for data analysis. Descriptive statistics were analyzed by means and standard deviations for continuous variables and frequencies and percentages for categorical variables. Repeated observations were compared using a paired t-test or repeated measures. Analysis of variance as applicable. P<0.05 was taken as statistically significant.

#### Inclusion criteria

- Patients posted for elective maxillofacial surgeries under general anesthesia
- Those who gave informed written consent to be part of the study
- Age between 18 and 60 years
- ASA Physical Status I and II
- Limited or restricted mouth opening
- Mallampati score of III or IV.

#### Exclusion criteria

- Those who refused consent
- Patients with a known allergy to local anesthetic drugs
- History of frequent episodes of epistaxis or an isolated serious episode of epistaxis
- Pregnant patients, those with coagulopathies or bleeding disorders
- History of drug abuse, alcoholism, or psychiatric illnesses.

## RESULTS

In our study of 40 patients, there were 23 (57.50%) males and 17 (42.50%) females. There was a male preponderance, with the M: F ratio being 1:0.73 (Figure 1).

The analysis of the patients on the basis of mean age showed that the most common age group was 41–50 years (42.50%),

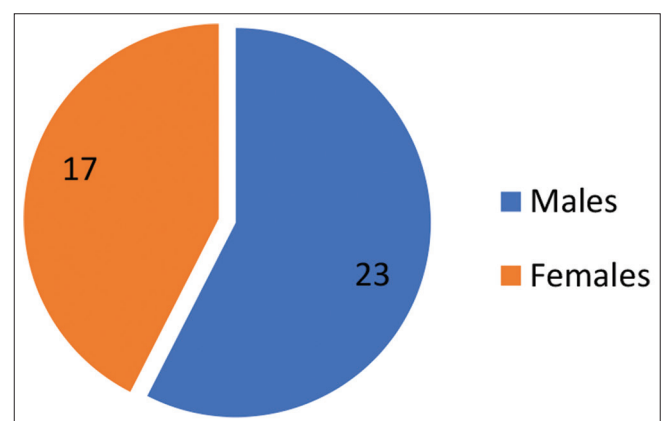


Figure 1: Gender distribution of the studied cases

followed by 31–40 years (27.50%), and 18–30 years (17.50%). 5 (12.50%) patients were between 51 and 60 years of age. Analysis of the patients based on ASA grades showed that there were 21 (52.50%) patients with ASA grade I and 19 (47.50%) patients with ASA grade II (Table 1).

Out of 40 patients, 28 (70%) had a mouth opening of <10 mm (70%), whereas 10–20 mm of mouth opening was present in 11 (27.50%) and 1 (2.50%) had a mouth opening of 20–25 mm (Table 2).

In 36 (90%) of the patients, the intubation could be successfully done, whereas in 4 (10%) patients, the intubation could not be done. In 19 (47.50%) patients, blind nasal intubation was successfully done in the first attempt; 2 attempts were required in 15 (37.50%) patients, and 3 attempts were required in 2 (5%) patients. Out of the 4 patients in whom ABNI failed, 3 were uncooperative and in the remaining 1 patient, it couldn't be successfully done despite 3 attempts (Table 3).

Out of 40 patients, 36 (90%) didn't have any intraoperative complications, whereas in 4 (10%) patients, epistaxis occurred. In the post-operative period, 34 (85%) patients had no complications. 3 (7.5%) patients developed a sore throat, 2 (5%) patients had hoarseness of voice, and 1 (2.50%) patient developed sinusitis in the post-operative period (Figure 2).

## DISCUSSION

Maxillofacial surgeries often pose unique challenges for anesthetists, particularly in the context of airway

management. Traditionally, securing the airway in these patients was primarily accomplished through techniques like orotracheal intubation and fiber-optic bronchoscopy. However, as clinical practices evolved and technology advanced, innovative approaches, including ABNI assisted by capnography, emerged.<sup>9</sup>

Though orotracheal intubation can be used in patients undergoing maxillofacial surgeries. Nevertheless, it frequently presented difficulties due to issues such as limited mouth opening, distorted anatomy, and an increased risk of trauma. To address these challenges, fiber-optic bronchoscopy was introduced. This technique revolutionized airway management by allowing direct visualization of the airway anatomy and the ability to navigate around obstructions. It became especially valuable for complex maxillofacial surgeries. However, one significant drawback of this technique was the requirement for a cooperative and adequately sedated patient, which is not always feasible.<sup>10</sup>

The development of ABNI marked a significant advancement in managing difficult airways, specifically in patients with anticipated airway challenges. ABNI involves intubating the patient through the nasal route while they remain either awake or lightly sedated, preserving essential airway reflexes. A key milestone in the evolution of ABNI was the integration of capnography. Capnography involves continuous monitoring of EtCO<sub>2</sub> levels. This addition provided real-time, objective confirmation of successful intubation and ventilation. The presence of EtCO<sub>2</sub> indicates that the endotracheal tube is in the correct position, a crucial consideration in maxillofacial surgeries where airway distortion can complicate intubation.<sup>11</sup>

**Table 1: Age distribution of the studied cases**

Age groups and ASA grades	Count	%
Age group		
18–30 years	7	17.50
31–40 years	11	27.50
41–50 years	17	42.50
51–60 years	5	12.50
Total	40	100.00
Mean age	40.97±8.92	
ASA grades		
ASA I	21	52.50
ASA II	19	47.50
Total	40	100.00

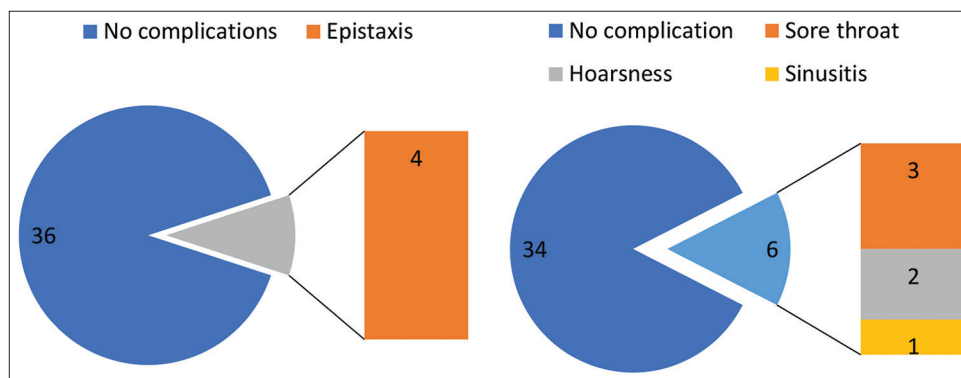
**Table 2: Mouth opening in studied cases**

Mouth opening	No of cases	Percentage
<10 mm	28	70.00
10–20 mm	11	27.50
20–25 mm	1	2.50
Total	40	100

**Table 3: Number of attempts and success of blind nasal intubation**

Intubation attempts and success of intubation	Count	Percentage
No of attempts for awake blind nasal intubation		
1	19	47.50
2	15	37.50
3	2	5.00
Failed	4	10.00
Total	40	100.00
Successful versus failed awake blind nasal intubation		
Successful	36	90.00
Failed	4	10.00
Total	40	100.00
Cooperation of patients		
Cooperative	37	92.50
Non-cooperative	3	7.50
Total	40	100.00





**Figure 2:** Intraoperative (left) and post-operative (Right) complications in studied cases

In our study, most of the patients had a mouth opening of <10 mm, and hence, reduced mouth opening was the primary reason to go for ABNI. Vadepally *et al.* conducted a comparative study to test intubation through the nasal route in patients with a limited mouth opening of <2 cm.<sup>12</sup> In this study, 18 patients required maxillofacial surgical procedures to increase mouth opening. Indications for this technique were mandibular fracture (n=6), oral submucous fibrosis (n=6), temporomandibular joint (TMJ) ankylosis (n=4), and internal derangement of the TMJ (n=2). All patients were assessed for preoperative interincisal opening during intubation through specific parameters, and postoperative findings were also observed. The mean time taken for successful intubation was 5.6 min ± 1.66. One patient had subcutaneous emphysema, which was managed conservatively. Limited mouth opening is one of the common indications for alternative ways of intubations reported by authors such as Wu *et al.*<sup>13</sup> and Tsay *et al.*<sup>14</sup>

In our study, in 36 (90%) of the patients, intubation could be successfully done, whereas in 4 (10%) patients, intubation could not be done. In 19 (47.50%) patients, awake nasal intubation was successfully done in the first attempt; 2 attempts were required in 15 (37.50%) patients, and 3 attempts were required in 2 (5%) patients. Sankar *et al.* conducted a study to determine the morbidity or mortality associated with the blind awake intubation technique in temporomandibular ankylosis patients.<sup>15</sup> For this purpose, 48 radiographically and clinically confirmed cases of temporomandibular joint ankylosis were included in the study for evaluation of anesthetic management and its complications. Blind awake intubation was done in 92% of cases; 6% of cases were intubated by fiber-optic awake intubation; and 2% of patients required surgical airway. Ninety-eight percent of the patients were cooperative during the awake intubation. The frequent complications encountered during the blind-awakened intubation were epistaxis and a sore throat. The success rate of orotracheal intubation in this study was similar to ours. Similar success

rates of awake nasal intubation were also reported by authors such as Dhasmana *et al.*<sup>16</sup> and Yoo *et al.*<sup>17</sup>

Out of 40 patients, 36 (90%) did not have any intraoperative complications, whereas, in 4 (10%) patients, epistaxis occurred. In the post-operative period, 34 (85%) patients had no complications. 3 (7.5%) patients developed a sore throat, 2 (5%) patients had hoarseness of voice, and 1 (2.50%) patient developed sinusitis in the post-operative period. Overall, epistaxis was the most common complication in patients undergoing orotracheal intubation. Woodall *et al.* conducted a study in which two hundred anesthetists underwent airway endoscopy and attempted awake fiber-optic intubation (FOI) on a training course.<sup>18</sup> Complications were recorded, and each subject's response to the procedure was assessed. In this study, more than 1300 endoscopies were performed; 180 delegates were intubated, 175 by the nasal route, and five orally. Intubation was abandoned in 20 (10%) subjects. Nasal bleeding occurred in 20 (10%) subjects. Symptoms that could be attributed to lidocaine were reported by 71 (36%) subjects. Afterward, 2 (1%) subjects experienced rigors, and one developed a lower respiratory tract infection. The complications in this study were similar to those in our study, and epistaxis was found to be the most common complication. Similar complications were also reported by the authors, such as Yamamoto *et al.*<sup>19</sup> and Chauhan *et al.*<sup>20</sup>

#### Limitations of the study

The small number of cases was the first limitation of the study. Another limitation was the absence of comparison with other methods of airway management, such as FOI. A larger comparative study will be required to further substantiate the results and compare the complication rates.

## CONCLUSION

Capnography-assisted ABNI is an effective technique of airway management in patients undergoing maxillofacial surgeries and having limited mouth opening. Successful

blind nasal intubation could be done in the majority of cases without any patient developing serious intraoperative or postoperative complications.

## ACKNOWLEDGMENT

The authors would like to acknowledge the support extended by the faculty and staff of the Department of Anesthesiology at Dr. PDMMC and Hospital, Amravati, Maharashtra, India, for the support they extended to undertake this study.

## REFERENCES

- Wong J, Lee JS, Wong TG, Iqbal R and Wong P. Fiberoptic intubation in airway management: A review article. Singapore Med J. 2019;60(3):110-118.  
<https://doi.org/10.11622/smedj.2018081>
- Pierre R 2<sup>nd</sup> and Dym H. Endotracheal tube obstruction via turbinectomy during nasal intubation. Anesth Prog. 2018;65(4):255-258.  
<https://doi.org/10.2344/anpr-65-04-09>
- Yoo H, Choi JM, Jo JY, Lee S and Jeong SM. Blind nasal intubation as an alternative to difficult intubation approaches. J Dent Anesth Pain Med. 2015;15(3):181-184.  
<https://doi.org/10.17245/jdapm.2015.15.3.181>
- Tintinalli JE and Claffey J. Complications of nasotracheal intubation. Ann Emerg Med. 1981;10(3):142-144.  
[https://doi.org/10.1016/s0196-0644\(81\)80379-4](https://doi.org/10.1016/s0196-0644(81)80379-4)
- Chung YT, Sun MS and Wu HS. Blind nasotracheal intubation is facilitated by neutral head position and endotracheal tube cuff inflation in spontaneously breathing patients. Can J Anaesth. 2003;50(5):511-513.  
<https://doi.org/10.1007/BF03021066>
- Pintaric TS. Upper airway blocks for awake difficult airway management. Acta Clin Croat. 2016;55(Suppl 1):85-89.
- Linko K and Paloheimo M. Capnography facilitates blind nasotracheal intubation. Acta Anaesthesiol Belg. 1983;34(2):117-122.
- Kumar R, Mathur A, Kumar S, Gupta N, Kumar NG, and Gupta E. Blind nasal intubation in a 'breathing' manikin-an idea. J Anaesthesiol Clin Pharmacol. 2022;38(1):143-147.  
[https://doi.org/10.4103/joacp.JOACP\\_140\\_20](https://doi.org/10.4103/joacp.JOACP_140_20)
- Ramanathan G. Capnography-guided awake nasal intubation. Indian J Anaesth. 2010;54(2):177-178.  
<https://doi.org/10.4103/0019-5049.63639>
- Dhasmana S, Singh V and Pal US. Awake blind nasotracheal intubation in temporomandibular joint ankylosis patients under conscious sedation using fentanyl and midazolam. J Maxillofac Oral Surg. 2010;9(4):377-381.  
<https://doi.org/10.1007/s12663-010-0159-8>
- Erasmus PD. The use of end-tidal carbon dioxide monitoring to confirm endotracheal tube placement in adult and paediatric intensive care units in Australia and New Zealand. Anaesth Intensive Care. 2004;32(5):672-675.  
<https://doi.org/10.1177/0310057X0403200512>
- Vadepally AK, Sinha R and Kumar AV. Retrograde intubation through nasal route in patients with limited mouth opening undergoing oral and maxillofacial surgery. J Oral Biol Craniofac Res. 2018;8(1):30-34.  
<https://doi.org/10.1016/j.jobcr.2017.08.002>
- Wu MY, Yiang GT, Ke JY, Chen CS, Lin PC and Chen YL. Role of trachway versus conventional modes of intubation in difficult airway management in COVID-19 setups. Emerg Med Int. 2021;2021:6614523.  
<https://doi.org/10.1155/2021/6614523>
- Tsay PJ, Yang CP, Luk HN, Qu JZ and Shikani A. Video-assisted intubating stylet technique for difficult intubation: A case series report. Healthcare (Basel). 2022;10(4):741.  
<https://doi.org/10.3390/healthcare10040741>
- Sankar D, Krishnan R, Veerabahu M, Vikraman BP and Nathan JA. Retrospective evaluation of airway management with blind awake intubation in temporomandibular joint ankylosis patients: A review of 48 cases. Ann Maxillofac Surg. 2016;6(1):54-57.  
<https://doi.org/10.4103/2231-0746.186126>
- Dhasmana S, Singh V and Pal US. Awake blind nasotracheal intubation in temporomandibular joint ankylosis patients under conscious sedation using fentanyl and midazolam. J Maxillofac Oral Surg. 2010;9(4):377-381.  
<https://doi.org/10.1007/s12663-010-0159-8>
- Yoo H, Choi JM, Jo JY, Lee S and Jeong SM. Blind nasal intubation as an alternative to difficult intubation approaches. J Dent Anesth Pain Med. 2015;15(3):181-184.  
<https://doi.org/10.17245/jdapm.2015.15.3.181>
- Woodall NM, Harwood RJ and Barker GL. Complications of awake fiberoptic intubation without sedation in 200 healthy anaesthetists attending a training course. Br J Anaesth. 2008;100(6):850-855.  
<https://doi.org/10.1093/bja/aen076>
- Yamamoto T, Flenner M and Schindler E. Complications associated with nasotracheal intubation and proposal of simple countermeasure. Anaesthesiol Intensive Ther. 2019;51(1):72-73.  
<https://doi.org/10.5603/AIT.a2019.0002>
- Chauhan V and Acharya G. Nasal intubation: A comprehensive review. Indian J Crit Care Med. 2016;20(11):662-667.  
<https://doi.org/10.4103/0972-5229.194013>

### Authors Contribution:

**MK**- Concept, design, clinical protocol, manuscript preparation, editing, and manuscript revision; **VK**- Design of study, statistical analysis and interpretation; **GD**- Review manuscript; Review manuscript; Literature survey and preparation of figures; **VB**- Coordination and manuscript revision.

### Work attributed to:

Dr Panjabrao Deshmukh Memorial Medical College and Hospital, Amravati, Maharashtra, India.

### Orcid ID:

Dr. Minal Kokate - <https://orcid.org/0009-0001-7057-9914>  
 Dr. Vikram Kokate - <https://orcid.org/0000-0002-6946-4319>  
 Dr. Gaurav Dubey - <https://orcid.org/0000-0002-6063-318X>  
 Dr. Vijaya Borkar - <https://orcid.org/0000-0001-7280-9747>

**Source of Support:** Nil, **Conflicts of Interest:** None declared.