

Clinical and dermoscopic profile of female pattern hair loss



Deepa John¹, Seena Palakkal², Mary Vineetha³

¹Junior Resident, ²Associate Professor, Department of Dermatology, Government Medical College, Kottayam, ²Assistant Professor, Department of Dermatology Venerology and Leprosy, Government Medical College, Konni, Kerala, India

Submission: 21-02-2023

Revision: 27-11-2023

Publication: 01-01-2024

ABSTRACT

Background: Female pattern hair loss (FPHL) is one of the hair loss disorders in women characterized by a gradual reduction in hair from the frontal, central, and parietal areas of the scalp. FPHL is more common than previously thought, and data regarding the same are lacking in the Indian literature. Unlike male pattern hair loss, there are not much studies regarding FPHL in South India. Hence, we intend to study the clinical features, associations, and dermoscopic findings of FPHL in our population. **Aims and Objectives:** The study was conducted to estimate the clinical and dermoscopic features of FPHL. The secondary objective of the study was to estimate the severity of FPHL based on clinical and dermoscopic features. **Materials and Methods:** The cross-sectional descriptive study was conducted in 300 patients who were clinically diagnosed with FPHL attending the Department of Dermatology, Government Medical College, Kottayam, during a period of 18 months from February 2021 to August 2022. **Results:** The mean age of patients with FPHL was 46.99 ± 13.8 years. The majority of the patients were asymptomatic. Hair diameter diversity of $>20\%$ and miniaturized hair were the most common dermoscopic findings seen in all patients. Honeycombing and yew dots in dermoscopy were seen in 17 and 8.4% of patients, respectively. **Conclusion:** Dermoscopes are a useful tool to differentiate FPHL from other causes of diffuse hair loss that could mimic FPHL. The presence of yellow dots and honeycombs indicated advanced FPHL. Thus, dermoscopy helps in detecting early FPHL and initiating early treatment of this condition.

Key words: Female pattern hair loss; Dermoscopy; Hair diameter diversity

INTRODUCTION

Female pattern hair loss (FPHL) is the most common hair loss disorder in women. FPHL has emerged as the preferred term for androgenetic alopecia (AGA) in females.¹ FPHL is nonscarring progressive thinning of hair with a gradual decrease in the number of hairs, especially in the frontal, central, and parietal scalp, with sparing of the frontal hair line. It is due to a progressive decrease in the ratio of the terminal to vellus hair – a process known as follicular miniaturization.² The role of androgen in the development of female pattern baldness has not been fully demonstrated, hence the term FPHL.^{1,2}

The frequency of FPHL varies among population groups and ordinarily increases with age.² The age of onset of

FPHL is later than that seen in men. 25% of women develop clinically detectable FPHL by age 49 years, 41% by age 69 years, and over 50% have some element of FPHL by age 79 years. Only 43% of women aged 80 years and above show no evidence of FPHL.¹

The most common endocrinologic comorbidity that is associated with FPHL is polycystic ovarian syndrome, followed by metabolic syndrome. FPHL may be viewed as a marker for an increased risk of cardiovascular and metabolic disease. FPHL is found to cause social anxiety, depression, and increased levels of emotional stress.¹ The earliest diagnostic feature of FPHL is a hair shaft diameter variation of $>20\%$ hair shafts with dermoscopy.³ Thus, dermoscopic examination helps in identifying FPHL and to initiate treatment at the earliest.

Access this article online

Website:

<http://nepjol.info/index.php/AJMS>

DOI: 10.3126/ajms.v15i1.52670

E-ISSN: 2091-0576

P-ISSN: 2467-9100

Copyright (c) 2024 Asian Journal of Medical Sciences



This work is licensed under a Creative Commons Attribution-NonCommercial 4.0 International License.

Address for Correspondence:

Dr. Seena Palakkal, Assistant Professor, Government Medical College, Konni, Kerala, India. **Mobile:** +91-9446792079.

E-mail: drseenapalakkal@gmail.com

Though it is a common distressing condition, few studies are there assessing the severity of FPHL and its associated comorbidities as well as dermoscopic findings. The objective of this study was to estimate clinical and dermoscopic features of FPHL and to estimate the severity of FPHL based on clinical and dermoscopic features.

Aims and objectives

- 1) To estimate clinical and dermoscopic features of female pattern hair loss
- 2) To estimate severity of female pattern hair loss based on clinical and dermoscopic features.

MATERIALS AND METHODS

The approval of the institutional ethical board was obtained from Government Medical College, Kottayam Institutional Review Board under the letter number (IRB no. 282021). This was a cross-sectional descriptive study conducted on 300 patients who were clinically diagnosed with FPHL and attended the Department of Dermatology, Government Medical College, Kottayam, during a period of 18 months from February 2021 to August 2022. The study population includes females aged more than 18 years with clinical features of FPHL attending the Dermatology Department of Government Medical College, Kottayam. A random sampling method was used.

A detailed history, including age of onset, duration of symptoms, and personal and family history of FPHL, was obtained. Every patient was subjected to a thorough general, physical, and dermatological examination. Each case is classified according to the Sinclair hair density severity scale for FPHL into various grades, where grade 1 is considered to be normal and grade 2 and above shows widening of the central scalp and thinning of hair on either side. Patients in grade 2 or higher on the Sinclair scale are considered to have FPHL. Hair shedding is assessed using a visual scale produced by Sinclair and also by using a hair pull test. In the hair pull test, a bundle of 50–60 hairs is grasped between the thumb, index finger, and middle finger from the base near the scalp and tugged firmly. When more than 10% of grasped hairs (i.e., on average, more than 6 hairs) are pulled out, the test is considered positive. This is positive during active phases in the affected area. Hair diameter diversity and other detailed examinations are done using the DermLite 3N dermoscope. The main dermoscopic features of FPHL are a hair diameter diversity of >20% and the loss of terminal hairs in follicular units (FUs). Hair diameter diversity is assessed at a point 2 cm from the frontal hair line in the midline and is compared with the occipital scalp. With these findings, the severity of FPHL can be assessed using the FPHL severity index (FPHL SI). To collect the required

information from eligible participants, a pre-structured proforma was used.

Sample size will be calculated by the formula $4pq/d^2$, and the P value obtained from a study conducted by Fabbrocini *et al.*, the percentage of FPHL is 25%.¹ So $P=25%$, $q=75%$, $d=\text{absolute precision}=20\%$ of $P=5$. $\text{Sample size}=4pq/d^2=300$.

The data was entered in a Microsoft Excel spread sheet and analyzed by Statistical Package for the Social Sciences software. For descriptive statistics, the mean and standard deviation were calculated. Inferential statistics were analyzed by the Chi-square test and Fischer's exact test.

Inclusion criteria

Females of more than 18 years of age with clinically diagnosed FPHL who provided consent for inclusion in the study were recruited.

Exclusion criteria

The exclusion criteria were as follows: pregnant and lactating women, women who underwent chemotherapy in <1 year, those using minoxidil or antiandrogens for more than 3 months, and women using hormone replacement therapy or oral contraceptive pills were excluded.

RESULTS

300 patients with FPHL were included in this study from February 2021 to August 2022 (18 months). The age of patients ranged from 18 to 84 years, with a mean age of 46.99 ± 13.8 years. The highest frequency was seen in the fifth decade. The mean age of onset was 36.26 ± 7.8 years, with the lowest being 16 and the highest being 58 years. The majority of the patients had a visible vertex of the scalp as their presenting complaint. The majority of the patients were asymptomatic. Associated symptoms like itching, scaling, and pain were seen in 25% of patients. About half of the patients had a duration of >10 years, with a mean duration of 13.71 ± 7 years. Nearly half of the study group attained menopause. As the duration of symptoms increase, patients with established FPHL also increases and most of them were in the post-menopausal group ($P < 0.001$). Fifty-four percent of the study group had comorbidities like diabetes mellitus, hypertension, dyslipidemia, and heart disease. Established FPHL was seen in postmenopausal women. This was found to be statistically significant. A family history of FPHL was seen in nearly a quarter of patients. Most of the patients with established FPHL had a Sinclair hair shedding score of 1–4, indicating that daily hair shedding was low in established FPHL. A positive hair pull test was seen in 4% of patients.

The hair pull test is positive in early FPHL. The majority of patients with positive hair pull tests (8 patients) had early FPHL (P<0.001).

Sinclair midline hair density grades 4 and 5 were seen in established FPHL. This finding was found to be statistically significant with P<0.001 (Fisher’s exact test) (Table 1).

Hair diameter diversity of >20% and miniaturized hair were seen in all patients. All patients with early FPHL had no difference in the proportion of single-hair FUs over the frontal and occipital scalps. Patients with established FPHL had a difference in the proportion of single hair per FU over the frontal scalp compared to the occipital scalp. (P<0.001 by Fisher’s exact test). Honeycombing and the presence of yellow dots were seen in established FPHL (P<0.001) (Table 2).

Of 300 patients, 236 patients (79%) had established FPHL with FPHL SI of ≥10, and 64 patients (21%) had early FPHL with FPHL SI between 5 and 9 (Table 3).

DISCUSSION

FPHL is one of the most common causes of non-scarring hair loss. FPHL causes significant psychological stress in patients.¹ Even though the diagnosis is clinical, it needs to be differentiated from other causes of diffuse hair loss. There are specific dermoscopic features of FPHL that help to exclude other causes of diffuse hair loss and avoid scalp biopsy.³

In this study, we evaluated dermoscopic findings in 300 patients with FPHL. In our study, the maximum number of cases (29%) were in the age group of 40–49 years, followed by 25% in 50–59 years, and the least (1%) in <20 years. The mean age was 46.99 years, with the youngest being 18 years and the oldest being 84 years. The frequency of FPHL increases with age. The majority of cases (53%) in our study noticed the onset of hair loss between the ages of 30 and 39, and few patients (1%) had onset before 20 years of age. The lowest age of onset was 16 and the highest 58 years. The mean age of onset of FPHL was 36.26±7.8 years. The maximum number of cases (57%) had a duration of AGA >10 years. 4% had a duration of <1 year. The mean duration of FPHL was 13.71±7 years. As the duration of FPHL increase, the number of patients with established FPHL also increases. This was statistically significant with P<0.001. In a study by Fabbrocini et al., 12% of women first develop clinically detectable FPHL by 29 years of age, 25% of women develop clinically detectable FPHL by 49 years of age, 41%

Table 1: Sinclair midline hair density grade and FPHL

Sinclair grade	Number of patients	Percentage
Grade 2	133	44
Grade 3	107	36
Grade 4	43	14
Grade 5	17	6

FPHL: Female pattern hair loss

Table 2: Dermoscopic findings in FPHL

Dermoscopic findings	Number of patients	Percentage
No difference in proportion of single FU over frontal area compared to occipital scalp	80	27
25–50% of FU in frontal area are single	144	48
50–75% of FU are single	56	18
≥75% of FU are single	20	7
Presence of short vellus hair Over frontal scalp	200	67
Honey comb appearance over frontal scalp	50	17
Yellow dot	20	8.4

FPHL: Female pattern hair loss, FU: Follicular units

Table 3: FPHL severity index

Severity of FPHL	Number of patients	Percentage
Early (5–9)	64	21
Established (≥10)	236	79

FPHL: Female pattern hair loss

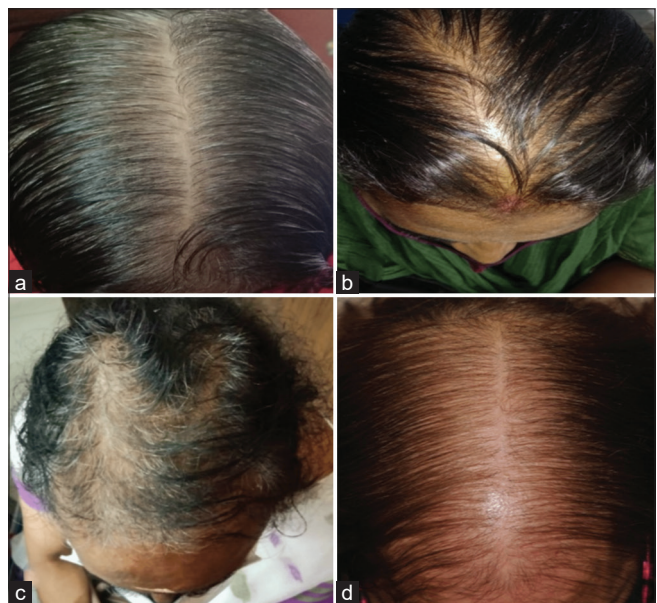

Figure 1: Clinical Images of scalp. (a) Sinclair grade 2 female pattern hair loss (FPHL), (b) Sinclair grade 3 FPHL, (c) Sinclair grade 4 FPHL, (d) Sinclair grade 5 FPHL

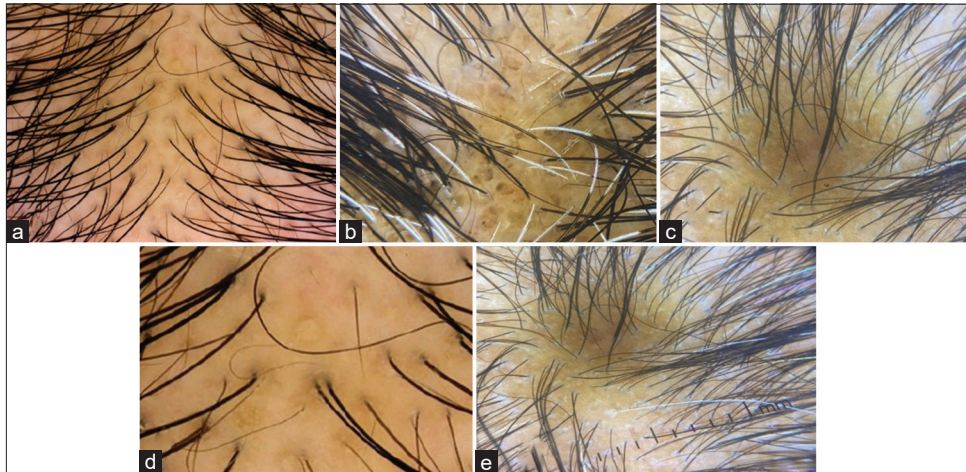


Figure 2: Dermoscopic images of scalp. (a) Anisotrichosis with miniaturized hair, (b) Short vellus hair, (c) Single hair per follicular unit, (d) Yellow dot, (e) Honeycombing

by 69 years, and over 50% have some element of FPHL by 79 years. We also noticed that the onset of FPHL occurs during the reproductive years.¹

In our study, the majority of patients (69%) had visible vertex of the scalp as presenting complaints, followed by excessive hair loss from the scalp in 18%, a reduction in hair density in 8%, and a hair line recession in 5%. The majority (75%) were asymptomatic. Associated symptoms were seen in 25% of patients, of which 4% had pain, 21% had itching, and 10% had itching and scaling together. In the study by Ohn et al., itching was seen in 42.9%, pain in 9.5%, and scaling in 12.7% of cases, which was higher than that noted in our study.⁴ In our study, menopause was attained in 144 patients (48%). The severity of FPHL is also high in postmenopausal women ($P < 0.001$). In a study by Chaikittisilpa et al., the prevalence of FPHL in postmenopausal women was 52.2% (Figure 1).⁵

The hair pull test was positive in 4% (11) patients, out of which the majority (8) had early FPHL ($P < 0.001$). In an article by Sinclair, a hair pull test is positive in early cases of patterned baldness.⁶ On assessing Sinclair midline hair density, out of 300 patients, 133 (44%) had Sinclair grade 2, 107 (36%) had grade 3, 43 (14%) had grade 4, and 17 (6%) had grade 5. Kaneko and Kaneko observed that out of 228 patients, Sinclair grade 1 was seen in 13%, grade 2 in 28%, grade 3 in 27%, grade 4 in 22%, and 10% had grade 5 (Figure 2).⁷

In our study, out of 64 patients with early FPHL, 54 (84%) had Sinclair midline hair density grade 2, and 10 (16%) had grade 3. Out of 236 patients with established FPHL, 97 (41%) had Sinclair midline hair density grade 3; 79 (33.4%) had grade 2; 43 (18.2%) had grade 4; and 17 (7.2%) patients had grade 5. With the increasing severity of FPHL, midline hair density also reduces, and a greater number of patients have grade 4 or 5 midline hair

density. This finding was found to be statistically significant ($P < 0.001$) by Fisher's exact test. In a study by Kaneko and Kaneko, out of 64 patients with grade 2 midline hair density, 63 had early FPHL, and out of 23 patients in grade 5 Sinclair midline hair density, 12 had established FPHL.⁷ This finding was in concordance with ours.

In our study, anisotrichosis (hair diameter diversity of more than 20%) was seen in all patients, and an increase in the number of vellus hairs was seen in 200 patients (67%). 220 patients (73%) had more single hair per FU as compared to the occipital scalp. In an age-matched cross-sectional study with 230 cases and 230 controls by Nagar and Dhudshia, all the cases in the frontal area showed anisotrichosis and an increase in the number of vellus-like hairs when compared to their own occipital scalp. A hair follicle unit containing a single hair was also observed in a significant number of cases in the frontal area when compared to their own occipital scalp.⁸ This was concordant with our study.

In our study, yellow dots were seen in 20 cases (8.4%). A study by Nagar and Dhudshia found that yellow dots were seen in 17 (7.4%) cases, and this finding is similar to ours. All the patients with yellow dots had established or advanced FPHL, which was statistically significant (Fisher's exact test).

Honeycomb was seen in 50 patients (21.1%) in our study, and all these patients had advanced or established FPHL, which was statistically significant (Fisher's exact test). In an article by Jain et al., it was found that honeycomb was seen in advanced patterned baldness due to excessive tanning.⁹ This finding was in concordance with ours.

Limitations of the study

- 1) Due to non availability of video dermoscope, fine measurements of hair related parameters were not

- made
- 2) Short study period
 - 3) Hormonal assays and sonography was not made.

CONCLUSION

FPHL is one of the hair loss disorders in women characterized by a gradual reduction in hair from the frontal, central, and parietal areas of the scalp. The maximum number of cases is seen in the fifth decade. FPHL causes significant psychological stress in patients. There is a significant association between the severity of FPHL and comorbidities. But this was not studied in detail, unlike AGA in men in literature. A dermoscope is a useful tool to differentiate FPHL from other causes of diffuse hair loss that could mimic FPHL. Hair diameter diversity of >20% is considered diagnostic of FPHL. The presence of yellow dots and honeycombs indicated advanced FPHL. Thus, dermoscopy helps in detecting early FPHL and initiating early treatment of this condition.

ACKNOWLEDGMENT

Dr Seena Palakkal and Dr Mary Vineetha had equally contributed to this study.

REFERENCES

1. Fabbrocini G, Cantelli M, Masarà A, Annunziata MC, Marascax C and Cacciapuoti S. Female pattern hair loss: A clinical, pathophysiologic, and therapeutic review. *Int J Womens Dermatol.* 2018;4(4):203-211. <https://doi.org/10.1016/j.ijwd.2018.05.001>
2. Oslen EA. Female pattern hair loss. *J Am Acad Dermatol.* 2001;45(3 Suppl):S70-S80. <https://doi.org/10.1067/mjd.2001.117426>
3. Bhamla A, Dhurat S and Saraogi P. Is trichoscopy a reliable tool to diagnose early female pattern hair loss? *Int J Trichol.* 2013;5(3):121-125. <https://doi.org/10.4103/0974-7753.125603>
4. Ohn J, Son HY, Yu DA, Kim MS, Kwon S and Park WS. Early onset female pattern hair loss: A case-control study for analysing clinical features and genetic variants. *J Dermatol Sci* 2022;106(1):21-28. <https://doi.org/10.1016/j.jdermsci.2022.02.011>
5. Chaikittisilpa S, Rattanasirisin N, Panchaprateep R, Orprayoon N, Phutrakul P, Suwan A, et al. Prevalence of female pattern hair loss in postmenopausal women: A cross sectional study. *Menopause.* 2022;29(4):415-420. <https://doi.org/10.1097/GME.0000000000001927>
6. Sinclair R. Femal pattern hair loss : A pilot study investigating combination therapy with low-dose oral minoxidil and spironolactone. *Int J Dermatol.* 2018 ;57(1):104-109. <https://doi.org/10.1111/ijd.13838>
7. Kaneko A and Kaneko T. A new classification of early female pattern hair loss. *Inj J Trichology.* 2018;10(2):61-67. https://doi.org/10.4103/ijt.ijt_80_17
8. Nagar R and Dhudshia R. Indian J Utility of trichoscopy to diagnose early female pattern hair loss in resource poor-setting: A cross-sectional study. *Dermatol Venereol Leprol.* 2019;85(6):681-689. https://doi.org/10.4103/ijdvl.IJDVL_826_18
9. Jain N, Doshi B and Khopkar U. Trichoscopy in alopecias: Diagnosis simplified. *Int J Trichology.* 2013;5(4):170-178. <https://doi.org/10.4103/0974-7753.130385>

Authors Contribution:

Dr Seena Palakkal and Dr Mary Vineetha had equally contributed to this study.

Work attributed to:

Department of Dermatology, Venerology and Leprosy, Government Medical College, Kottayam, Kerala, India.

Orcid ID:

Dr. Deepa John - <https://orcid.org/0009-0005-2853-3903>
 Dr. Seena Palakkal - <https://orcid.org/0000-0003-4577-378X>
 Dr. Mary Vineetha - <https://orcid.org/0000-0002-5295-6093>

Source of Support: Nil, **Conflicts of Interest:** None declared.