

'Hemophagocytosis' a small yet relevant bone marrow aspirate finding: experience of a tertiary care pediatric centre in India



Nita Radhakrishnan¹, Neema Tiwari², Savitri Singh³, Jyotsna Madan⁴, Devajit Nath⁵, Usha Bindal⁶, Ravi Shankar⁷

¹Assistant Professor, ²Fellowship Resident, Paediatric Hemato-Oncology, ³Senior Resident, ⁴Associate Professor, ⁵Professor and Head, ⁶Assistant Professor, Department of Pathology, ⁷Associate Professor, Department of Bio-chemistry, Super Speciality Paediatric Hospital and Post Graduate Teaching Institute, Noida

Submission: 08-09-2020

Revision: 05-11-2020

Publication: 01-01-2021

ABSTRACT

Background: Hemophagocytosis (HS) is an interesting finding that is observed in bone marrow, lymph nodes, CSF other reticuloendothelial systems but at times is overlooked or is not incorporated in reports. Demonstration of hemophagocytosis is one criterion in the diagnosis of Hemophagocytic Lymphohistiocytosis (HLH). **Aims and Objective:** Hemophagocytosis as an important finding evaluated in pediatric bone marrows having different clinical diagnosis. **Materials and Methods:** A retrospective descriptive analysis of bone marrow aspirates of 73 patients showing any degree of hemophagocytosis [out of 440 bone marrow aspirates] retrieved from the archives of Department of Pathology during the period from May 2017 to May 2020 were included in the study. Only those cases where microscopic examination revealed hemophagocytosis (73 cases) were included in the study. **Results:** On analysing the data of 73 bone marrow aspirate 11 (1 Primary, 10 secondary) cases were confirmed clinicopathologically as Hemophagocytic lymphohistiocytosis, 9 cases (2 metastasis, 4 infective, 1 acute leukemia, 1 nutritional deficiency and 1 Hypocellular marrow with degenerative changes) were not suspected to have HLH clinically however showed features of increased serum ferritin >500mg/dl and bone marrow aspirate hemophagocytosis, favouring a diagnosis of secondary HLH (WHO 2004) **Conclusion:** We present a spectrum of differential diagnosis presenting with hemophagocytosis in pediatric population and its clinico-biochemical correlation assessing progression to HLH.

Key words: hemophagocytosis; pediatric; bone marrow aspiration

INTRODUCTION

Hemophagocytosis (HS) is an interesting finding that is observed in bone marrow, lymph nodes, CSF other reticuloendothelial systems but at times is overlooked or is not incorporated in reports. It is defined as engulfment of erythrocytes, leukocytes, platelets, and their precursors by the histiocytes either in the bone marrow or in other parts of the reticuloendothelial system.¹ However, the presence of hemophagocytosis may be associated with variety of conditions including infections (bacterial, viral or fungal), autoimmune, neoplasms or some storage disorders. Hemophagocytosis may also be seen occasionally in post

chemotherapy marrow.^{2,3} Exaggeration of the basic functions of a macrophage leads to its over-activation with increase in the phagocytic activity where a macrophage engulfs not only cell debris but also intact cells of any lineage.⁴

Demonstration of hemophagocytosis is one criterion in the diagnosis of Hemophagocytic Lymphohistiocytosis (HLH). Very few studies have reported pediatric hemophagocytic lymphohistiocytosis even when it is not a rare disease. HLH is a distinct clinical entity in which excessive uncontrolled activation, proliferation of T-cells and macrophages occur and is often proves fatal if not treated. First described in 1939 by Scott and Robb-Smith as a histiocytic

Access this article online

Website:

<http://nepjol.info/index.php/AJMS>

DOI: 10.3126/ajms.v12i1.31067

E-ISSN: 2091-0576

P-ISSN: 2467-9100

Copyright (c) 2021 Asian Journal of Medical Sciences



This work is licensed under a Creative Commons Attribution-NonCommercial 4.0 International License.

Address for Correspondence:

Dr. Savitri Singh, Department of Pathology, Super Speciality Paediatric Hospital & Post Graduate Teaching Institute, Sector-30, Noida, Uttar Pradesh, Pin Code- 201303, India. **Mobile:** +91-9873727332. **E-mail:** savipath8@gamil.com

reticulosis, a neoplastic proliferation of histiocytes, this syndrome has since then been given several other denominations, including hemophagocytic histiocytosis, histiocytic disorder, macrophage activation syndrome, and reactive hemophagocytic lymphohistiocytosis (HLH).^{5,6} Hemophagocytic syndromes occur commonly secondary to bacterial or viral infections. They either occur in previously healthy individuals or as a terminal complication in patients with altered immune response.⁷ The primary form of HLH is a fatal disease if untreated.⁸

Since the Indian data is very limited specially in paediatric population on hemophagocytosis in bone marrow, we retrospectively analysed the pediatric bone marrow aspirates from the archives of department of pathology.

MATERIAL AND METHODS

A retrospective descriptive analysis of bone marrow aspirates of 73 patients [out of 440 bone marrow aspirates] retrieved from the archives of Department of Pathology during the period from May 2017 to May 2020 were included in the study. All cases with any degree of hemophagocytosis reported in bone marrow aspirate smears were part of analysed. Clinical information was obtained from the requisition forms sent with the bone marrow samples. The slides were stained with Romanowsky stain, haematoxylin and eosin and special stains like PAS and Perl's stain where ever needed. Ziehl-Neelson Stain for Acid fast bacilli was also done where suspected.

The bone marrow aspirate smears were examined by 4 independent pathologists to remove any bias in the study. Presence or absence of any degree of hemophagocytosis was noted and matched clinically and biochemically. All cases showing hemophagocytosis were included in the study. Cases with a previously diagnosed HLH who were on follow up were excluded.

RESULTS

The results of analysing the clinical, biochemical and pathological findings in the above data we tabulated as follows:

On analysing the data of 73 bone marrow aspirate cases for clinical and pathological findings it is seen that 11(1 Primary,10 secondary) out of 73 cases were confirmed clinically as well as on aspirate examination and by correlation with serum ferritin as Hemophagocytic lymphohistiocytosis, 9 cases (2 metastasis, 4 infective, 1 acute leukemia, 1 nutritional deficiency and 1 Hypocellular marrow with degenerative changes) were not suspected to have HLH clinically however

showed features of increased serum ferritin >500mg/dl and bone marrow aspirate hemophagocytosis, favouring a diagnosis of secondary HLH (WHO 2004) However, there was no clinical suspicion of HLH in these 09 cases and their presence could be explained as co-existing pathology with the primary disease process (Table 1). In the Table 1 cases tabulated under acute leukemia had a recently diagnosed case of leukemia those presented with respiratory complaints and was COVID positive. She presented with features of secondary HLH and biopsy showed clusters of macrophages with hemophagocytosis. These findings had initially masked the morphology of the blasts, which resembled virocytes and we discuss this case here to bring out the importance of a pediatric case presenting as HLH which was actually had acute leukemia (Figures 1-7).

In primary HLH (Griscelli's syndrome), the patient progressed to involvement of the CNS on subsequent follow ups.

It is seen that it is easier to morphologically delineate debris laden, hemosiderin laden macrophages from hemophagocytosis in marrow aspirates than in bone marrow biopsies. Also an important point to keep in mind is that processing and reporting of biopsies can take up to minimum 3 days while processing and reporting of bone marrow aspirates/Imprint can be done as early as 2 hrs. Hence, we analysed the bone marrow aspirate smears for other features apart from Hemophagocytosis which were present in the aspirate smears and those findings are tabulated below in Table 2.

The above table highlights other significant findings seen in the bone marrow aspirates examined which accompanied hemophagocytosis (Table 2).

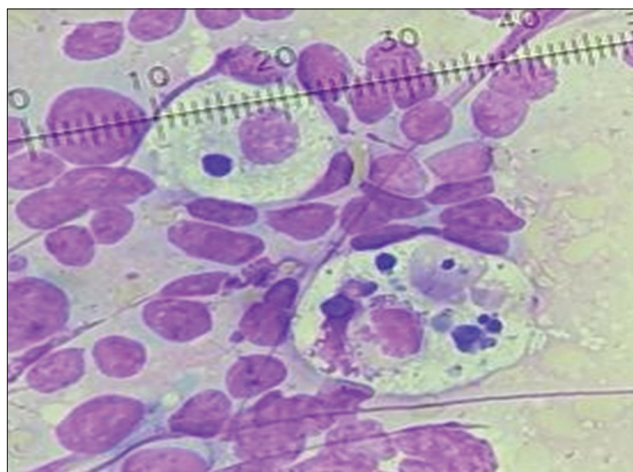
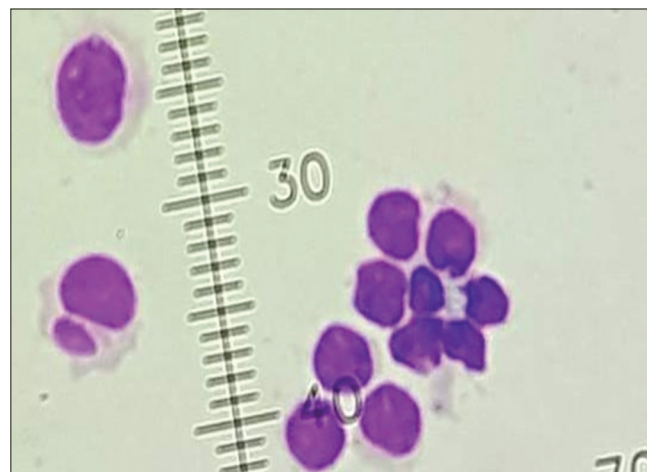
We used Perl's stain to detect iron storage levels in the 20 cases where hemophagocytosis with increased ferritin levels were seen to assess iron storage levels and found that Grade 4 iron stores were seen in 2 out of 4 cases of confirmed HLH. However, grade 2 iron stores was seen in one suspected case of HLH while a case of megaloblastic anemia with hemophagocytosis showed grade 1 iron stores.

DISCUSSION

The syndrome of hemophagocytosis has to be first recognized as a primary or secondary process.⁹ It has also been associated with a variety of viral, bacterial, fungal, and parasitic infections, as well as with collagen-vascular diseases and malignancies, particularly T-cell malignancies.¹⁰⁻¹² The association between HS and infection is important because both sporadic and familial

Table 1: Clinico-Pathological, biochemical interpretation and outcome

Pathological interpretation	No of cases	Hemophagocytosis in BMA	Ferritin above 500mg/dl	HLH confirmed in cases after clinic-serological and pathological correlation	Outcome
Hypocellular marrow with degenerative changes, tri-lineage suppression and dyspoiesis	3	Present	Present in 1	1	Stable
GrisCELLI syndrome	1	Present	Present	1	Died
Secondary HLH	9	Present	Present	9	Stable
Erythroid hyperplasia with megaloblastic changes, dyspoiesis	7	Present	Absent	0	Stable
Nutritional deficiency with secondary maturation arrest post infective/ megakaryocytic hyperplasia	7	Present	Present in 1 out of 6 cases	1	Stable
Marrow in MR post chemo(hypocellular/cellular)	16	present	Present in one out of 16 cases	1	Stable
Acute leukemia(AML/ALL)	3	Present-2 Absent-1	1 out of 3	1	Stable
Cellular marrow ?infective(?TB?VIRAL)	7	present	Present in 4 out of 7 cases	4	Stable on follow up
Reactive marrow	3	present	absent	0	stable
Megakaryocytic hyperplasia(ITP)	6	present	absent	0	stable
Metastasis	5	present	Present in 2 out of 5 cases	2	Stable
NSHL					
Neuroblastoma					
NHL?ALCL					
HD					
Ewing's Sarcoma					
Others		-	-	-	-
Storage Disorder	2				
Thalassemia	1				
Neutropenia	1				
Lymphoid Leukemoid reaction	1				

**Figure 1:** (Romanowsky stained 400X) Imprint smear in acute leukemia with hemophagocytosis**Figure 2:** (Romanowsky stained 400X) Fluid cytology (CSF) of primary HLH with hemophagocytosis

cases of HLH are often precipitated by acute infections; HLH mimics overwhelming infectious sepsis, misleading diagnosis and may obscure the diagnosis of precipitating treatable infectious illnesses, including visceral leishmaniasis and tuberculosis.⁹⁻¹³ The diagnosis of HLH can be made if there is a family history of HLH or evidence of genetic defects or if 5/8 clinicopathological criteria are fulfilled.¹⁴

Etiopathogenesis of HLH is explained in many papers as response to infection, innate and adaptive elements of the immune system to clear the pathogen and generate memory cells of adaptive immunity.^{15,16} In a physiologic (normal) situation, triggering of the immune system by an intracellular organism leads to transient activation and expansion of the lymphohistiocytic compartment.

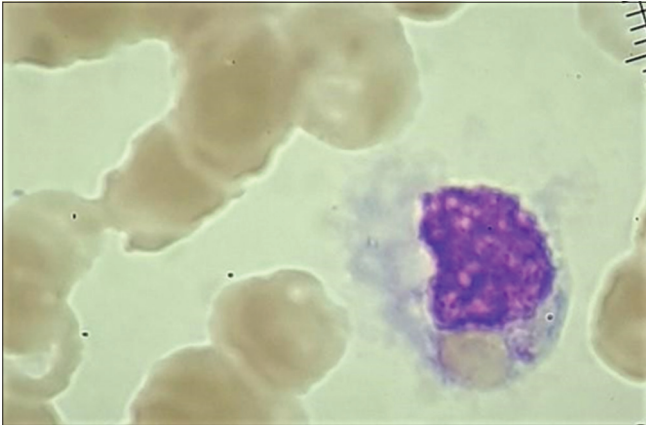


Figure 3: (Romanowsky stained 400X) peripheral smear showing Hemophagocytosis in 21days infant (post-operative)

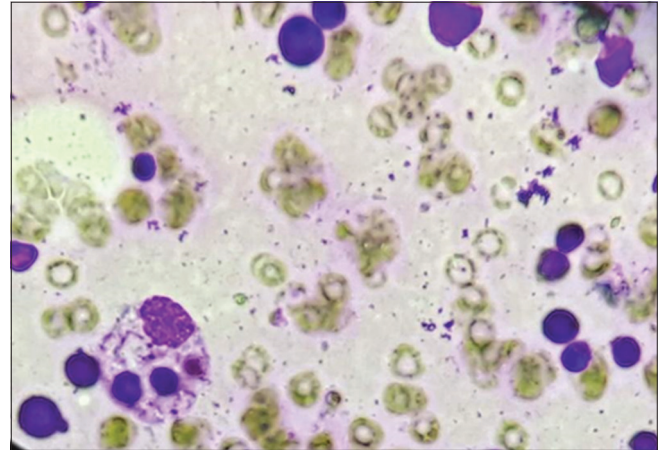


Figure 6: (Romanowsky stained,400x)W Hemophagocytosis in a case of typhoid in bone marrow aspirate

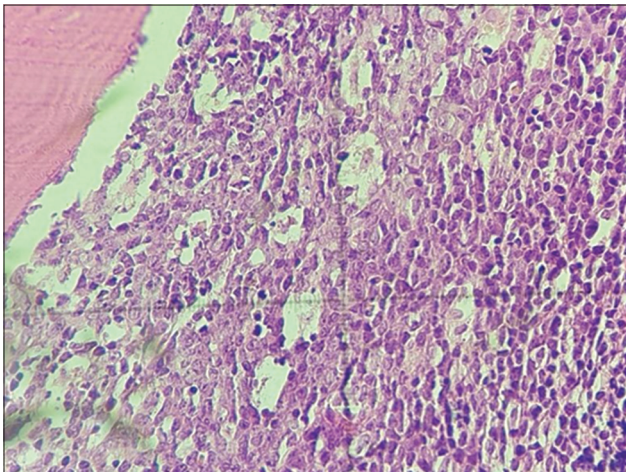


Figure 4: (H&E,400X) Histiocytes admixed with blasts with few showing debris and occasional hemophagocytosis in a case of COVID positive case of Acute Leukemia

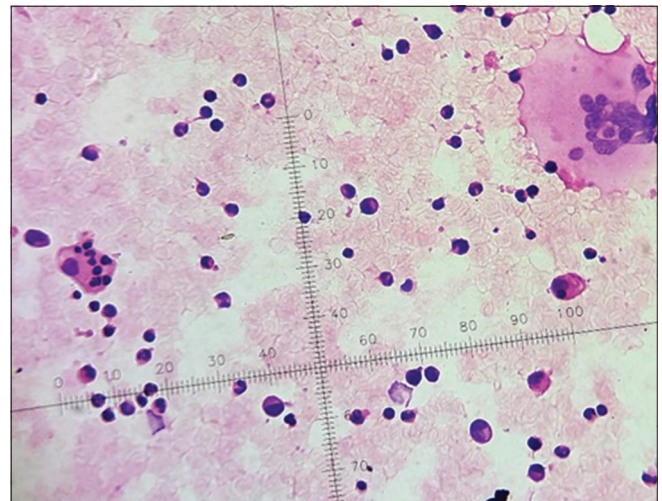


Figure 7: (H&E stained 100x) Hemophagocytosis with a megakaryocyte (HnE)

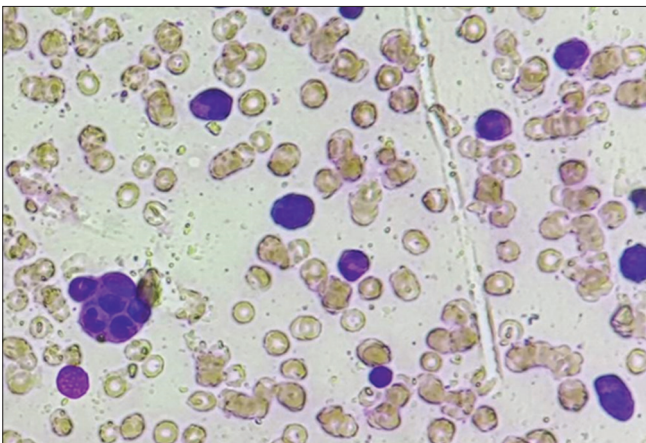


Figure 5: (Romanowsky stained,100x) Hemophagocytosis in bone marrow aspirate of a case of anemia

Transient production of interferon-(INF-) leads to transient expansion and activation of both the lymphocyte and macrophage compartments. The intensity of the immune response depends on the type of infecting antigen,

its structure, dose, localization, and duration of infection in the host. Once the initial infection has been cleared, control of the response in normal individuals results in contraction of the immune system and a return to baseline for both lymphoid and macrophage lineages, with generation of a few memory T and B cells.^{17,18}

While studying the 73cases retrospectively we saw that 2 out of the 11 cases where HLH was clinically confirmed had lymphopenia which could be because of viral or even bacterial infection such as typhoid. Later on typhoid serology came positive and secondary HLH due to typhoid was confirmed. One case of Griscelli's syndrome was diagnosed post clinic-pathological and biochemical correlation and the findings of microscopic examination of patient's hair strands as well as molecular analysis. Unfortunately, the patient expired as HLH progressed with involvement of the CNS, where his CSF showed marked hemophagocytic activity in large activated monocytes.

Table 2: Relevant bone marrow findings in cases with hemophagocytosis (one BMA/BMI at times showed multiple findings)

Feature	Number of cases
Eosinophilia	06
Monocytosis	29
Perl's stain showing increased iron deposits between grade 1-grade 4	04
Reticulocyte count >1%	05
Increased mast cells	02
Atypical lymphocytosis	02

Most cases on peripheral smears presented with cytopenias, few of them clinically were suspected as HLH. We had a single case 21 day old male infant [postoperative follow up] with thrombocytopenia on CBC, which was our youngest case showing hemophagocytosis in peripheral smear. As seen in all other studies, we also saw that infection was the most important reason for HLH. In one study done on 25 marrows all showed the presence of hemophagocytosis.¹⁸ Clinical features and presence of cytopenia are important diagnostic criteria for HLH and can be helpful in discriminating hemophagocytosis due to infection and other causes from hemophagocytosis due to HLH.¹⁸⁻²⁰

Multiple studies acknowledge the occurrence of secondary HLH in hematolymphoid malignancies and also as a consequence of chemotherapy [trogenic immunosuppression]. In a study of six patients with HLH the presence of hemophagocytosis in the bone marrow had a sensitivity of 83% in detecting HLH.⁵ In our study we also diagnosed a 15 year old female who presented with features of pancytopenia and respiratory distress, diagnosed as COVID-19 positive ,not responding to treatment, as ALL with hemophagocytosis when a bone marrow aspirate and biopsy were performed. The presence of hemophagocytosis in the bone marrow aspirates should be the guiding principle for further workup to rule out HLH.¹¹

We analysed other features present in a marrow showing hemophagocytosis whether qualifying for HLH or not and observed features like eosinophilia, monocytosis. Features of erythroid hyperplasia, megaloblastic changes, dyspoiesis were also seen. This is similar to previous literature where associated bone marrow findings observed in the study including dysplasia, normoblastic erythroid hyperplasia or hypocellular marrow which may be due to the primary disease.¹² An important finding that was observed in the study was that hemophagocytosis was of moderate to severe grade (2+ to 3+) in HLH cases showing hemophagocytosis on bone marrow examination and may prompt for other investigations to confirm HLH.¹¹ Few authors have observed in their study that 58% of

patients with HLH had at least one hemophagocytosis per 500 nucleated cells and concluded that the number of hemophagocytosis at initial bone marrow aspirate is low and variable and should be reported.¹⁶

Hence, we saw that although HLH is clinically diagnosed entity fair number of times close examination of the bone marrow aspirate may give an idea about an impending HLH and the a thorough clinico-serological evaluation of such patients should be done. We have tried to summarise our experience in the field of pediatric hemophagocytosis observed in bone marrow aspirates in this study.

Take home message

The importance of thorough examination of bone marrow aspirate (minimum 3smears) to pick up hemophagocytosis which can point to an impending HLH has been highlighted here. Clinico-pathological correlation is of great relevance in any case where even one cell showing hemophagocytosis is seen. Hemophagocytosis is a nonspecific finding while examining bone marrow aspirate smears. In most cases, it is not clinically taken significant unless it is one among HLH criteria. Pathologists play a critical role in diagnostic work up of both clinically suspected as well as non-suspected cases in confirming or ruling out HLH as finding of hemophagocytosis in bone marrow aspirate [low cost test] is one of the criteria for diagnosis.

ACKNOWLEDGEMENT

I (We) thank my staff Ms Pallavi, Mr Utkarsh, Mr Mahesh, Mr Mayank for all their help.

REFERENCES

- Hasegawa D, Kojima S, Tatsumi E, Hayakawa A, Kosaka Y, Nakamura H, et al. Elevation of the serum Fas ligand in patients with hemophagocytic syndrome and Diamond-Blackfan anemia. *Blood*. 1998; 91:2793-2799. https://doi.org/10.1182/blood.V91.8.2793.2793_2793_2799
- Stepp SE, Mathew PA, Bennett M, de Saint Basile G and Kumar V. Perforin: more than just an effector molecule. *Immunol Today*. 2000; 21:254-256. [https://doi.org/10.1016/S0167-5699\(00\)01622-4](https://doi.org/10.1016/S0167-5699(00)01622-4)
- de Saint Basile G and Fischer A. The role of cytotoxicity in lymphocyte homeostasis. *Curr Opin Immunol*. 2001; 13:549-554. [https://doi.org/10.1016/S0952-7915\(00\)00257-0](https://doi.org/10.1016/S0952-7915(00)00257-0)
- Stinchcombe J, Bossi G and Griffiths GM. Linking albinism and immunity: the secrets of secretory lysosomes. *Science*. 2004; 305:55-59. <https://doi.org/10.1126/science.1095291>
- Lay JD, Tsao CJ, Chen JY, Kadin ME and Su IJ. Upregulation of tumor necrosis factor-alpha gene by EpsteinBarr virus and activation of macrophages in Epstein-Barr virus-infected Tcells in the pathogenesis of hemophagocytic syndrome. *J Clin Invest*. 1997; 100:1969-1979.

- <https://doi.org/10.1172/JCI119728>
6. Fisman DN. Hemophagocytic syndromes and infection. *Emerg Infect Dis.* 2000; 6:601-608.
<https://doi.org/10.3201/eid0606.000608>
 7. Schneider EM, Lorenz I, Muller-Rosenberger M, Steinbach G, Kron M and Janka-Schaub GE. Hemophagocytic lymphohistiocytosis is associated with deficiencies of cellular cytolysis but normal expression of transcripts relevant to killer-cell-induced apoptosis. *Blood.* 2002; 100:2891-2898.
<https://doi.org/10.1182/blood-2001-12-0260>
 8. Egeler RM, Shapiro R, Loechelt B and Filipovich A. Characteristic immune abnormalities in hemophagocytic lymphohistiocytosis. *J Pediatr Hematol Oncol.* 1996; 18:340-345.
<https://doi.org/10.1097/00043426-199611000-00002>
 9. Farquhar J and Claireaux A. Familial haemophagocyticreticulosis. *Arch Dis Child.* 1952; 27:519-525.
<https://doi.org/10.1136/adc.27.136.519>
 10. Henter JI, Elinder G, Soder O and Ost A. Incidence in Sweden and clinical features of familial hemophagocytic lymphohistiocytosis. Diagnostic guidelines for hemophagocytic lymphohistiocytosis. The FHL Study Group of the Histiocyte Society. *Acta Paediatr Scand.* 1991; 80:428-435.
<https://doi.org/10.1111/j.1651-2227.1991.tb11878.x>
 11. Chandra H, Chandra S, Kaushik R, Bhat N and Shrivastava V. Hemophagocytosis on bone marrow aspirate cytology: Single center experience in North Himalayan region of India. *Ann Med Health Sci Res.* 2014;4:692-696.
<https://doi.org/10.4103/2141-9248.141515>
 12. Henter JI, Horne A, Aricó M, Egeler RM, Filipovich AH, Imashuku S, et al. HLH-2004: Diagnostic and therapeutic guidelines for hemophagocytic lymphohistiocytosis. *Pediatr Blood Cancer.* 2007; 48:124-131.
<https://doi.org/10.1002/pbc.21039>
 13. Goel S, Polski JM and Imran H. Sensitivity and specificity of bone marrow hemophagocytosis in hemophagocytic lymphohistiocytosis. *Ann Clin Lab Sci.* 2012; 42:21-25.
 14. Oliveira C, Chacim S, Ferreira I, Domingues N and Mariz JM. Secondary hemophagocytic syndrome: The importance of clinical suspicion. *Case Rep Hematol.* 2014;958425.
<https://doi.org/10.1155/2014/958425>
 15. George MR. Hemophagocytic lymphohistiocytosis: Review of etiologies and management. *J Blood Med.* 2014; 5:69-86.
<https://doi.org/10.2147/JBM.S46255>
 16. Park KH, Yu HS, Jung SI, Shin DH and Shin JH. Acute human immunodeficiency virus syndrome presenting with hemophagocytic lymphohistiocytosis. *Yonsei Med J.* 2008;49:325-328.
<https://doi.org/10.3349/ymj.2008.49.2.325>
 17. Campbell JI, Kanters S, Bennett JE, Thorlund K, Tsai AC, Mills EJ, et al. Comparative effectiveness of induction therapy for human immunodeficiency virus-associated cryptococcal meningitis: A network meta-analysis. *Open Forum Infect Dis.* 2015; 2:ofv010.
<https://doi.org/10.1093/ofid/ofv010>
 18. Janka GE and Lehmborg K. Hemophagocytic lymphohistiocytosis: Pathogenesis and treatment. *Hematology Am Soc Hematol Educ Program.* 2013; 2013:605-611.
<https://doi.org/10.1182/asheducation-2013.1.605>
 19. Maakaroun NR, Moanna A, Jacob JT and Albrecht H. Viral infections associated with haemophagocytic syndrome. *Rev Med Virol.* 2010; 20:93-105.
<https://doi.org/10.1002/rmv.638>
 20. Padhi S, Ravichandran K, Sahoo J, Varghese RG and Basheer A. Hemophagocytic lymphohistiocytosis: An unusual complication in disseminated Mycobacterium tuberculosis. *Lung India.* 2015; 32:593-601.
<https://doi.org/10.4103/0970-2113.168100>

Author's contribution:

NR-Contributed by providing the cases and editing; **NT**-Editing, manuscript formulation; **SS**-Concept, manuscript formulation data analysis; **JM, DN**-Editing and Review; **UB**-Provided biochemical profile; **RS**-Clinical data.

Work attributed to:

Super Speciality Paediatric Hospital & Post Graduate Teaching Institute, NOIDA, Uttar Pradesh.

Orcid ID:

Dr. Savitri Singh-  <https://orcid.org/0000-0001-6558-9424>

Source of Funding: None, **Conflict of Interest:** None