

Fallopian tube carcinoma: Energy lost in diagnosing without the total benefit of chemotherapy

Neelam Pradhan, Sita Ghimire, Kesang D Bist and Reeta Manandhar
Dept of Obs/Gyn, TU. Teaching Hospital

Abstract

A post menopausal lady presented with vague symptoms of swelling in lower abdomen giving an impression of left adnexal mass clinically, with detection of similar finding on USG and CT scan, and an additional feature suggestive of liver metastases. On laparotomy this looked like a fallopian tube carcinoma and it was confirmed histologically, which showed infiltration of both the ovaries, left broad ligament, and cervix. FNAC of lymph node depicted metastatic adenocarcinoma, although the tumour markers and Pap test were negative. Patient's refusal to undergo chemotherapy turned down all the efforts made in making the diagnosis of this advanced malignancy.

Key words: Adnexal mass, fallopian tube carcinoma, tumour markers

Introduction

Primary fallopian tube cancer is one of the rare malignancies of female genital tract, its incidence being less than 1% among the gynaecological cancer. The etiological factors are poorly understood. But similarities of age group incidence, low parity and association with infertility suggest that the etiology may be similar to ovarian and endometrial carcinoma. The common age group for the occurrence of this carcinoma is 50-60 yrs with mean age of 55 yrs. It is found to be associated with primary infertility in more than 70% with 5 fold increases in the risk of bilateral involvement of the tube.¹ Usual presentation in 15% are triad of watery discharge, pelvic mass and pelvic pain. There may be history of a pelvic mass in about 60% or postmenopausal bleeding may be present in >50%. Histological features and behaviour of the tumour are similar to ovarian cancer, so the evaluation and treatment is also similar to that of ovarian carcinoma. Fallopian tube can be involved from the secondaries of ovaries, endometrium, gastro-intestinal tract and breast.

Case

A 56 yrs lady, housewife from Khotang, P₆L₅

menopausal since 7 yrs and a chronic smoker was admitted with the complaints of generalized weakness of lower limbs since one year followed by swelling over inguinal region bilaterally since 2 months. There was no history of postmenopausal bleeding. On examination she had pitting edema in the suprapubic region and in the sacral area. Inguinal lymph nodes were palpable on both sides which were one or two in number and were firm discrete and non-tender. There was no hepatosplenomegaly. Per speculum examination revealed healthy cervix, without any abnormal discharge or bleeding. A firm, fixed nodular growth 1×1 cm could be felt in POD more towards the left side, on bimanual examination. Left parametrium was thickened. Uterine size could not be assessed properly as it was fixed to the left side. Right fornix felt normal. No other separate mass could be felt through the fornices. A Pap smear and an endometrial biopsy were planned next day. In the mean time she was advised for an ultrasound. Because of the swelling over the suprapubic region, urologist was also consulted. Both the Pap smear and the endometrial biopsy were normal. FNAC from the lymph node was also taken.

But in USG a heterogeneous lesion in left adnexa measuring 2.6×2.4 cm in size was noted which was ditto in CT scan except that the left ovary was not visualized

Correspondence

Dr. Neelam Pradhan, Msc. Epi, FCPS
Assoc Prof, Dept of Obs/Gyn, T U. Teaching Hospital Kathmandu, Nepal.
Email: neelam.44@gmail.com

separately (Fig1). In addition there was an echogenic lesion with a hypoechoic rim measuring 3×2.59 cm in right lobe of liver (fig2) and another small lesion in left lobe in USG; where as CT scan picturized variable sized multiple hypo-dense lesions, 2 on left and 1 on right lobe of liver. Both CT and USG pictures giving an impression of a left adnexal pathology suggestive of ovarian carcinoma with liver metastasis. Liver function test (LFT) was normal and all the tumour markers for ovarian cancer, Ca-125, LDH, CEA, AFP, B-HCG were normal as well.

With the impression of ovarian carcinoma she underwent staging laparotomy. At laparotomy minimal straw-coloured ascitic fluid-was present that was sent for cytology. Dense adhesions were present between large bowel and left posterolateral wall of lower part of the body of uterus and posterior leaf of broad ligament. Uterus was normal in size and appeared normal. A small 1×1 cm firm whitish ovary like nodule was found in the pelvic floor on left side. The left fallopian tube contained 1×2 cm whitish ovary like mass irregular towards the fimbrial end which was adherent to the posterior leaf of broad ligament and to the metastatic nodule on the pelvic floor. Left ovary, right ovary and the right fallopian tube appeared normal. (fig 3 & 4)

Adhesiolysis was done followed by removal of metastatic nodule from POD, uterus, tubes and ovaries on both sides. Surgeon oncologist removed the metastatic nodule from right lobe of liver, the larger one, along with omental biopsy. On cut section, endometrial and cervical canal were empty and the ratio of uterus to cervix was 1:1. The fimbrial end containing tumour mass was rough, nodular with irregular surface and hard in consistency. So the post-operative diagnosis considered was primary carcinoma of fallopian tube, stage IV. Post-operative period was uneventful. She was discharged on 17th post-operative day and the tension sutures were removed on 30th day of operation.

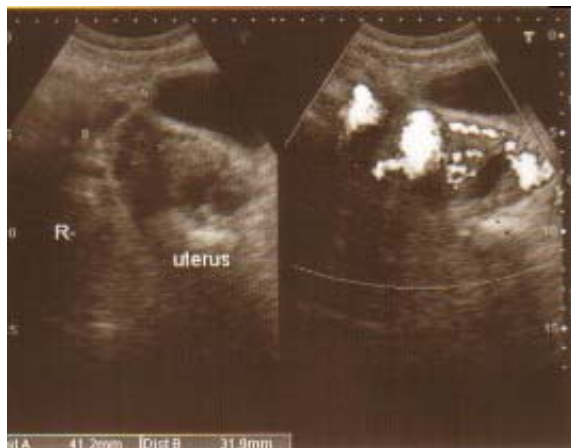

Fig 1. Doppler sonography of a vascular mass in the left adnexa.

Histopathology result was a poorly differentiated serous adenocarcinoma of left fallopian tube with depth of invasion through the serosa. Tumor infiltrations were seen on ovaries, left broad ligament and cervix. Lymphatic invasion was also present, while vascular invasion was absent. Histopathology from the growth on pelvic floor was also metastatic poorly differentiated adenocarcinoma while omentum was free from tumour infiltration. Biopsy of the liver nodule too did not show tumour infiltration except degeneration. FNAC of the lymph node was compatible with metastatic adenocarcinoma.

Patient was advised for adjuvant chemotherapy but refused because of economical problem. This happens in our Nepal. They leave us without even taking the first course of chemotherapy despite the counselling.

Discussion

Primary carcinoma of fallopian tube is very rare and because of this, the diagnosis is hardly made preoperatively. As said about the occurrence of tumour to be common in 55 years old postmenopausal women of low parity, our patient was 56 years and had attained menopause 7 yrs back, however, with high parity. Though more than 50% cases are claimed to be associated with postmenopausal bleeding and similarly further 50-60% have been associated with a pelvic mass, none of these features were present in this case. Generalized weakness and bilateral inguinal swelling were the reasons for seeking medical help. Clinically there was no appreciable pelvic mass except for a nodular growth in POD, a finding that is usually found in carcinoma ovary.

Duration of symptoms can be variable in fallopian tube carcinoma. It could be from 2 months to as long as 48 months; 50% of patients had symptoms and 6% did not.² Our case too had a duration of symptoms for 2 months although they were not specific to fallopian

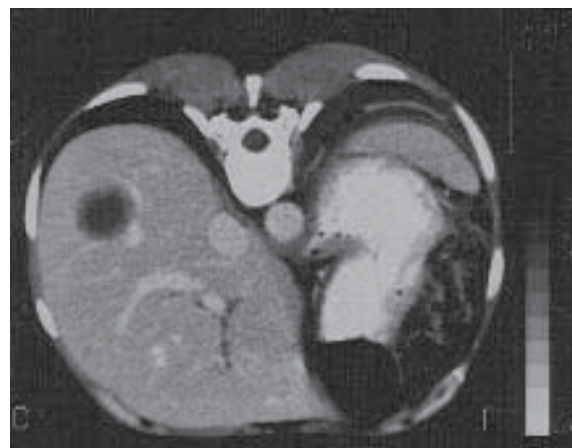

Fig 2. CT scans showing a heterogenous lesion in Rt lobe of liver suggesting metastasis

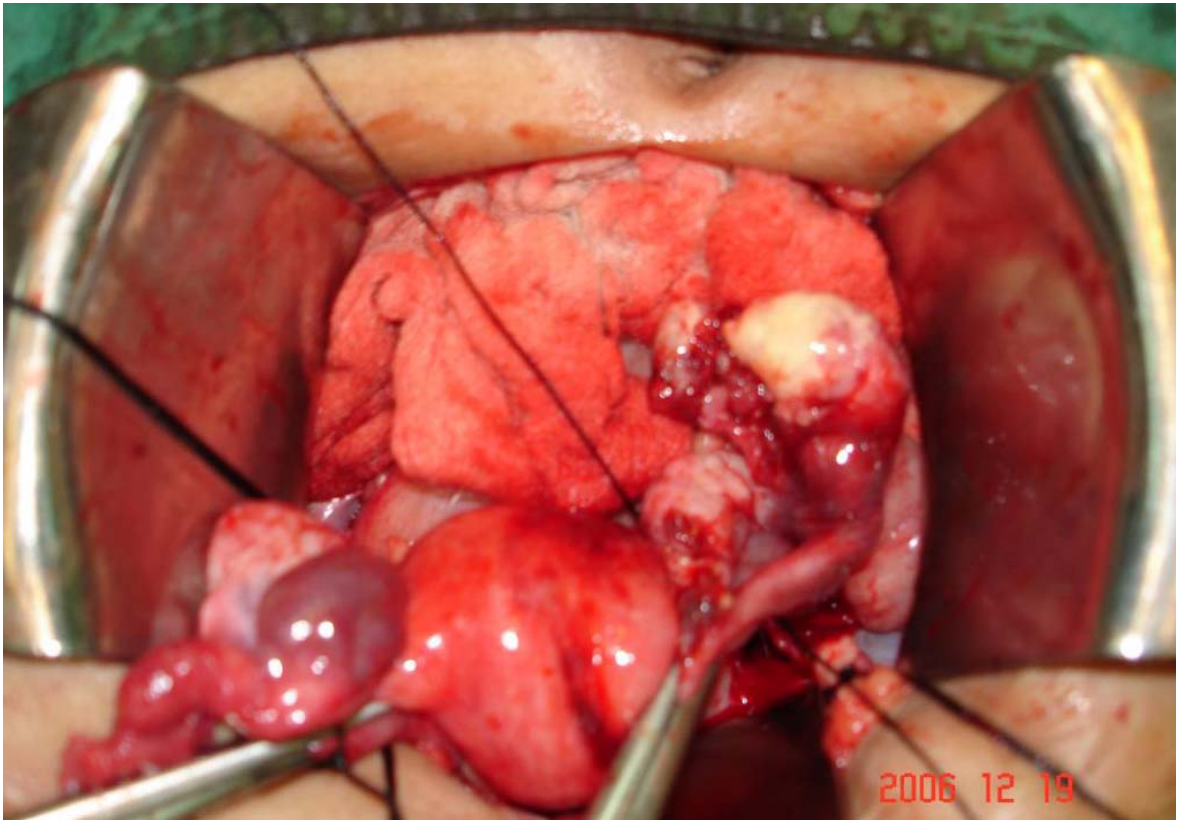


Fig 3. Per-operative finding: A 1X2 cm whitish ovary like irregular growth on the fimbrial end of the left tube with a separate normal looking ovary.

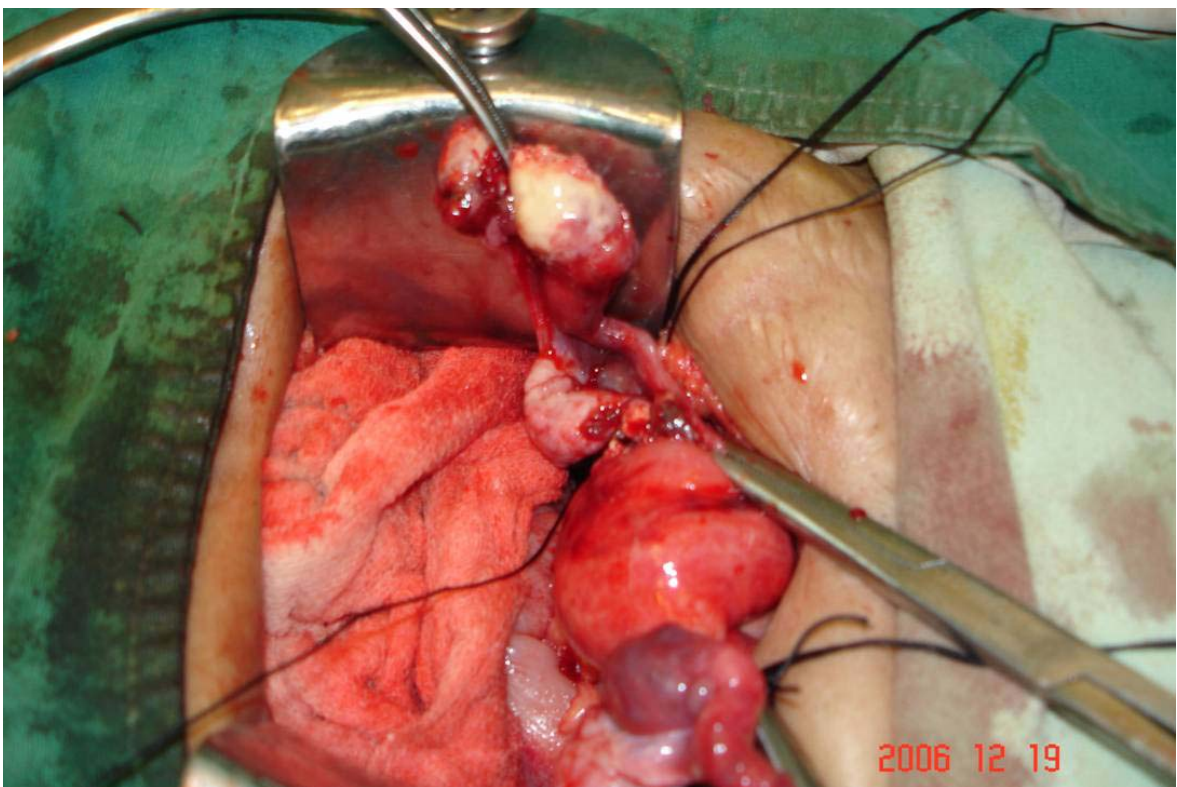


Fig 4. Mass arising from the fimbria is dissected.

tube malignancy.

Negatively tested though, Pap smear detection of fallopian tube carcinoma vouched to be 60%. This is not entirely true as detection was possible in 23 % of 115 women having positive cytology.³ In the smear field psammoma bodies may be seen as is met in ovarian malignancies.

Profuse vaginal discharge (hydrops tubae profound) draining to the cervix and discharging the malignant cells runs a possibility for positive Pap result. Absence of such a finding can be reasoned out for the negativity. Since USG and CT scan was suggestive of ovarian malignancy, tumour markers were also sent. But CA 125 was not raised, unlike fallopian tube carcinoma where 80% of the cases were found to have raised CA 125. Rests of the tumour markers were also inconclusive. USG and CT finding were inclined at the diagnosis, histology proving this.

Conclusion

Fallopian tube carcinoma though a rare tumour forms a differential diagnosis of any vague adnexal mass especially in a postmenopausal lady. Histopathology remains by far the gold standard in confirming the diagnosis and treatment alike ovarian carcinoma.

Reference

1. Mei-Liu M, Gan-Gao, Schong-Sun et al. Diagnosis of primary adenocarcinoma of the fallopian tube. *N Cancer Res Clin Oncol* 1985; 110:136.
2. Eddy GL et al. Fallopian tube carcinoma. *Obstet Gynecol* 1984; 64:546.
3. Peters WA, Anderson WA, Hopkins MD et al. Prognostic factors of carcinoma of the fallopian tube. *Obstet Gynecol* 1988; 71:757