

Original Article

Q-switched Nd:YAG Laser Treatment of Nevus of Ota: A Study of 25 Nepalese Patients

Shrestha S. B.¹, Khatiwada L.²

^{1, 2}Consultant Dermatologist, Nepal Korea Dongsan Medical Centre, Kathmandu, Nepal

Funding: None

Conflicts of interest: None

Abstract

Introduction:

Nevus of Ota is a dermal melanocytic nevus for which hitherto no effective therapy was available. It is common in Asian patients. Most patients seek treatment early in life due to the psychological trauma and cosmetic disfigurement. Prior treatments have been either ineffective or caused scarring. The Q-switched lasers have been successfully tried for the ablation of the lesion.

Aims and Objectives:

To evaluate long-term safety and efficacy of Q-switched Nd:YAG laser in pigmented lesion of 25 Nepalese patients.

Materials and Methods:

Twenty five patients of nevus of Ota underwent multiple treatments (average 8 sessions) carried out over a period of 2 years with Q-switched Nd:YAG laser (Model: WON-COSJET TR, South Korea). Of the 25 patients, five were males; and the rest, females. One patient had a bilateral involvement. The response of treatment was documented through serial photographs that were taken before and after the completion of each treatment. Patients were followed up for a period of 6 months after the last session. Response to treatment was graded based on physician's global assessment.

Results:

Excellent improvement was noted in majority of the patients at the end of the treatment. Greater-than-60% improvement was seen in 64% (n=16) of the patients. The remaining patients had moderate clearing of pigmentation (30%-60% improvement). No significant adverse effects were seen immediately after the treatments and on long-term follow-up. No recurrence was observed after 6 months of follow-up.

Conclusion:

This study validates the superior efficacy of Q-switched Nd:YAG laser when compared to conventional methods for treatment of nevus of Ota.

Keywords: Multiple treatments, Nevus of ota, Q-switched Nd:YAG laser

Address for correspondence:

Dr. Sanju Babu Shrestha

Consultant Dermatologist and Venereologist

Nepal Korea Dongsan Medical Centre,

Min Bhawan, Kathmandu, Nepal

P.O. Box No: 7134, Phone No: +9771 4621996,

E-mail: sanrekha2000@yahoo.com

Original Article**Introduction**

Nevus of Ota is a dermal melanocytic disease presenting as mottled, bluish or gray-brown lesion of eye and the surrounding skin innervated by the first and second branches of trigeminal nerve. This usually corresponds to forehead, temple, nose, eyelid, ear and scalp. It occurs predominantly in more darkly pigmented individuals, especially in Asians and blacks but has been described in whites as well. About 80% of all reported cases have been in women; however, this figure may be somewhat skewed as a result of a greater cosmetic concern in women.²

Nevus of Ota is the commonest in Asian patients and affects between 0.014% to 0.034% of the Asian population. The age of onset is bimodal, with larger peak at birth or soon after and a smaller peak at adolescence. Nearly all lesions appear by 30 years of age.³ The condition is more common in females, with a male-female ratio of 1:4.8. Cosmetic and psychological disturbances common concerns to affected individuals who may delay treatment because of doubt about final satisfactory fading. Treatment options were limited prior to the advent of lasers. Q-switched Nd:YAG laser (QSNYL) has been used successfully to treat a variety of benign, dermal, pigmented lesions, including nevus of Ota lesions. They have changed the approach in managing this condition and have become the mainstay of therapy.⁴

Aim of the study

The aim of the study was to document the safety and efficacy of Q switched Nd:YAG laser in Nepalese patients with naevus of Ota.

Materials and Methods

The study group comprised twenty-five patients (5 male and 20 female) with nevus of Ota, who were treated at Nepal Korea Dongsan Medical Centre, Min Bhawan, Kathmandu, Nepal, over a period of 2 years (from Oct. 2008 to Sept. 2010) with a Q-switched Nd:YAG laser (Model Won-Cosjet TR, South Korea). The nature of the procedure was fully explained and written informed consent was obtained from all the patients. shows the demographic profile of the

patients. Most patients were in the age group 21-25 years, with mean age being 23 years. One patient had bilateral involvement. The youngest patient treated was 18 years old, while the oldest was 35 years old. Skin type of the patients treated included phototypes 4 and 5.

Table 1: Demographic profile of patients

<i>Males</i>	<i>Females</i>
5	20
<i>Unilateral</i>	<i>Bilateral</i>
24	1
<i>Age groups (Years)</i>	<i>No. of patients</i>
16-20	3
21-25	16
26-30	4
31-35	2

Patients were advised to use sunscreen throughout the duration of treatment. Bleaching creams containing hydroquinone or kojic acid were used if the patients had tanned skin. Topical anesthesia with eutectic mixture of lignocaine and prilocaine was used one hour prior to treatment under plastic occlusion (2 applications at half hour interval) if the lesion being treated was a large one. Otherwise, no anesthesia was necessary. All personnel in the procedure room wore appropriate eye protection during laser treatment. During treatment, the patients wore eye shields provided by the manufacturer. Therapy was initiated with 1064-nm Q-switched Nd:YAG laser at fluences of 6.0 to 6.5 joules/cm², spot size 4 and frequency of 5 Hz. and the end point being immediate whitening of the lesion on laser irradiation. For the patients who did not yield any significant response with this dose, the fluence was subsequently increased to 7.0 joules/cm² for the rest of the sessions in all cases. In those cases where residual pigmentation was observed after 6 sessions, the fluence was increased to 11-13 J/cm² by reducing the spot size to 3 mm. After each treatment, patients were instructed to apply Fusidic acid cream for one week and sunscreen (SPF 30) and maintain it until the following session. Treatment was performed with the hand piece held perpendicular to the skin surface with

Original Article

minimal overlap (about 10%). The entire lesion was covered with a single pass. On an average the interval between laser treatments was 2 months. All patients completed a minimum of 6 treatments and were followed up for 6 months postoperatively. Photographs of naevus were obtained immediately prior to each treatment and during follow up. Response to treatment was graded based on physician's global assessment. Two physicians independently rated the clinical improvement as follows.

Excellent: Greater than 60% improvement
 Moderate: Between 30% and 60% improvement
 Poor: Less than 30% improvement (clearing)

Results

Excellent improvement was noted in a majority of the patients at the end of the treatments. Greater-than-60% improvement was seen in 64% (n=16) of the patients (Fig. 1 and 2). The remaining patients had moderate clearing of pigment (30%-60% improvement) but none of the patients showed poor response. Use of higher fluences gave better results, with most patients responding to the highest allowed energy of 7.0 J/cm² at 4-mm spot size. Use of a spot size of 3 mm was also associated with good clearing of pigment but with higher complication rate. The patients were followed up for 6 months after the last treatment session. On continued follow-up, it was observed that the pigment continued to lighten. No significant adverse effects were seen immediately after the treatments and on long-term follow-up. Transient post-inflammatory hyperpigmentation was observed in 3 (12%) patients, which cleared on use of sunscreens and bleaching agents within 2 months. No textural change or scarring was seen. Hypopigmentation (guttate type) was observed in 1 (4%) patient, which resolved within 3 months. No recurrence was observed during the 6 months follow-up.

Discussion

The treatment options for nevus of Ota prior to the advent of lasers has been limited. These included cryotherapy⁵, dermabrasion,⁶ surgical excision,⁷ and cosmetic camouflage. The surgical

treatment options were associated with significant scarring and permanent pigment alteration. Q switched (QS) lasers have changed the management of pigmentary lesions to a great extent.⁸

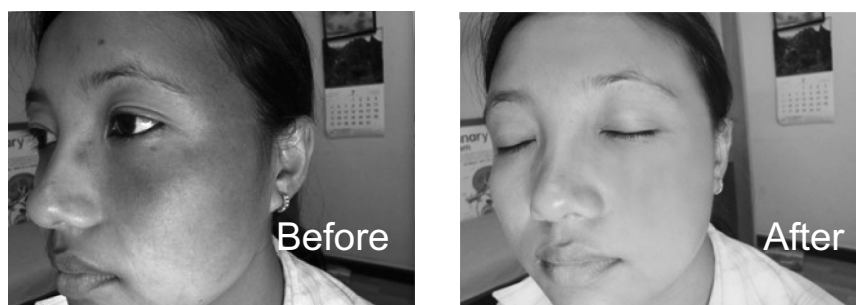
There have been previous studies in which Q switched lasers have been used for treating nevus of Ota. Geronemus⁹ treated 15 patients with QS ruby laser with greater than 50% clearing in all cases. The efficacy of QS ruby laser was later confirmed in another study involving 114 patients which demonstrated good clinical results with few side effects.¹⁰ Aurangabadkar S reported 60% improvement in 66% of patient and moderate improvement in remaining 34% patients.⁴ In similar study, Sharma S et al reported more than 70% improvement in 60% of patients, 32% had moderate improvement and 8% had mild improvement.

In our study, all patients responded well to treatment with 64% patients having more than 60% clinical improvement. We noticed that the therapeutic response was directly proportional to the number of treatment sessions. However, after 10-12 sessions there was no added improvement in the patients.

When the results of QS Nd: YAG laser are compared to QS Alexandrite laser, patients found a better tolerance to the latter. However, QS Nd: YAG laser is found to be more effective after 3 or more sessions. Hypopigmentation is a commonly reported problem with QS ruby laser. Overall, QS Nd: YAG laser is better suited to our skin type though the only limitation is that noticeable improvement may appear late and clinicians need to consider repeated treatments in such cases.

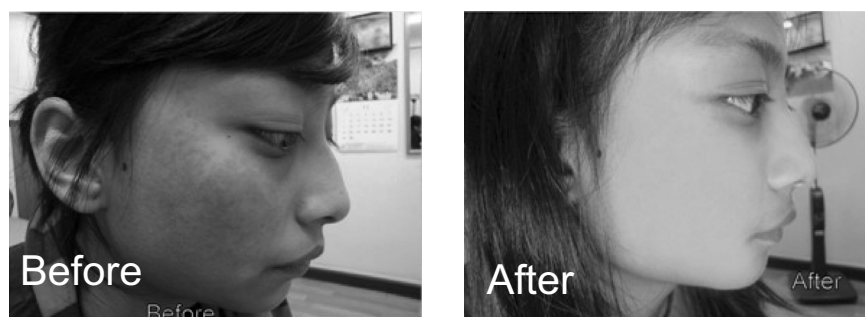
The side effects were few and all of them were reversible. The side effects in our study were comparable with the other Indian study by Aurangabadkar who reported transient hyperpigmentation (10%), hypopigmentation (2%) with no textural change or scarring.

Original Article



◀ **Figure : 1**
Patient with Naevus of Ota before treatment and after 8 treatment sessions

Figure : 2 ▶
Patient with Naevus of Ota before treatment and after 8 treatment sessions

**Conclusion**

QSYAG laser is an effective and safe treatment modality for nevus of Ota in Nepalese patients of phototypes 4 and 5. Side effects are few and mild.

References

1. Bhattacharya SK, Girgla HS, Singh G. Naevus of Ota. *Int J Dermatol* 1973; 12:344–7.
2. Bologna Jean L, Jorizzo Joseph L, Rapini Ronald P. *Dermatology*. second edition. Mosby Elsevier: 2008;
3. Cowan TH, Balistocky M. The nevus of ota or oculodermal melanocytosis. *Arch Ophthalmol* 1961; 65:483–92.
4. Aurangabadkar S. Q-switched Nd:YAG laser treatment of nevus of Ota: An Indian study of 50 patients. *J Cutan Asthet Surg* 2008 Jul;1(2) :80-4.
5. Hidano A, Kajima H, Ikeda S, Mizutani H, Miyasato H, Niimura M. Natural history of nevus of ota. *Arch Dermatol* 1967; 95:187–95.
6. Hosaka Y, Onizuka T, Ichinose M, Yoshimoto S, Okubo F, Hori S, et al. Treatment of nevus of Ota by liquid nitrogen cryotherapy. *Plast Reconstr Surg* 1995; 95:703–11.
7. Hata Y, Matsuka K, Ito O, Matsuda H, Furuichi H, Ishizu N, et al. Treatment of nevus of Ota: Combined skin abrasion and carbon dioxide snow method. *Plast Reconstr Surg* 1996; 97:544–54.
8. Kilmer SL, Garden JM. Laser treatment of pigmented lesions and tattoos (review) *Semin Cutan Med Surg* 2000; 19:232–44.
9. Geronemus RG. Q-switched ruby laser therapy of nevus of Ota. *Arch Dermatol* 1992; 128:1618–22.
10. Goldberg DJ, Nychay SG. Q-switched ruby laser treatment of nevus of Ota. *J Dermatol Surg Oncol* 1992; 18:817–21.
11. Sharma S, Jha AK, Kumar S. Role of Q-switched ND: YAG laser in nevus of ota: A study of 25 cases. *Indian Journal of Dermatology* 2011;56(2):663-65
12. Chan HH, King WW, Chan ES, Mok CO, Ho WS, Van Krevel C, et al. In vivo trial comparing patients' tolerance of Q-switched Alexandrite (QS Alex) and Q-switched Neodymium: Yttrium-Aluminum-Garnet (QS Nd-YAG) lasers in the treatment of nevus of Ota. *Lasers Surg Med* 1999; 24:24–8.
13. Chan HH, Ying SY, Ho WS, Kono T, King WW. An in vivo trial comparing the clinical efficacy and complications of Q-switched 755 nm alexandrite and Q-switched 1064 nm Nd: YAG lasers in the treatment of nevus of Ota. *Dermatol Surg* 2000; 26:919–22.