

# Balloon Pulmonary Valvuloplasty in patients with Congenital Valvular Pulmonary Stenosis

Sharma R<sup>1</sup>, Rajbhandari R<sup>1</sup>, Limbu Y<sup>1</sup>, Singh S<sup>1</sup>, Bhatt YKD<sup>1</sup>, KC MB<sup>1</sup>

<sup>1</sup>Department of cardiology, Shahid Gangalal National Heart Centre, Kathmandu, Bansbari.

## Abstract

### Background

Congenital valvular pulmonary stenosis (PS) accounts for most of the etiology of PS, and constitutes about 5 to 10% of all congenital heart disease. Balloon Pulmonary Valvuloplasty has become the choice of treatment for valvular PS since the first series reported by Kan et al in 1982<sup>4</sup> and has almost replaced surgical valvotomy in pediatric patients. The purpose of this study was to investigate the immediate results of balloon valvuloplasty in patients with congenital valvular pulmonary stenosis.

### Method

We analyzed hemodynamic data of 122 patients who underwent balloon pulmonary valvuloplasty (ages 14 days- 50 years mean 25 years). Single-balloon technique was used. Right ventricle systolic pressure and pulmonary valve Peak-to-peak systolic pressure gradient were recorded before and after balloon dilatation of pulmonary valve.

### Result

Right ventricle systolic pressure decreased from  $128 \pm 44.9$  to  $60 \pm 24.9$  mmHg ( $p < 0.001$ ) and pulmonary valve peak-to-peak systolic pressure gradient decreased from  $89 \pm 38.6$  to  $45 \pm 22.4$  mmHg ( $p < 0.001$ ). No major complication or mortality was noted.

### Conclusion

Balloon pulmonary valvuloplasty is a safe and effective treatment for patients with congenital valvular PS.

**Keywords:** Pulmonary stenosis, Balloon valvuloplasty

## Introduction

Congenital valvular pulmonary stenosis (PS) accounts for most of the etiology of PS, and constitutes about 5 to 10% of all congenital heart disease. The first use of a balloon catheter was reported in the early 1800s when a catgut balloon was used to dilate the urethra.<sup>1</sup> In 1979, Semb, et al. first introduced nonsurgical dilatation of stenotic pulmonary valve by balloon technique in a pediatric patient,<sup>2</sup> and later in 1982, Pepine et al first described successful balloon valvuloplasty in an adult patient.<sup>3</sup> BPV has become the choice of treatment for valvular PS since the first series reported by Kan et al in 1982<sup>4</sup> and has almost replaced surgical valvotomy in pediatric patients. The double-balloon technique was first reported by Al Kasab et al in 1987.<sup>5</sup> The use of two balloons may permit a small amount of blood flow between them even during full dilatation, and leads to fewer hemodynamic changes.<sup>6</sup> The use of Inoue balloon, which was first reported by Lau et al<sup>7</sup> also has advantages over the single-balloon technique because it is size-adjustable, making stepwise dilatation possible, and due to its short and self-positioning characters, minimizing the possible injury to RV infundibulum or main PA.<sup>8</sup> But Inoue balloon has disadvantages including necessity of a large sheath, rigid property and costly expense.

**It is recommended that the indications for intervention should include the following two criteria:**

1. Patients with exertional dyspnea, angina, syncope, or presyncope.
2. Asymptomatic patients with normal cardiac output (estimated clinically or determined by catheterization) and transvalvular peak systolic pressure gradient more than 30 mmHg.<sup>9</sup>

We used Single-balloon technique and here we present our experience of balloon valvuloplasty for patients with congenital PS.

## Methods

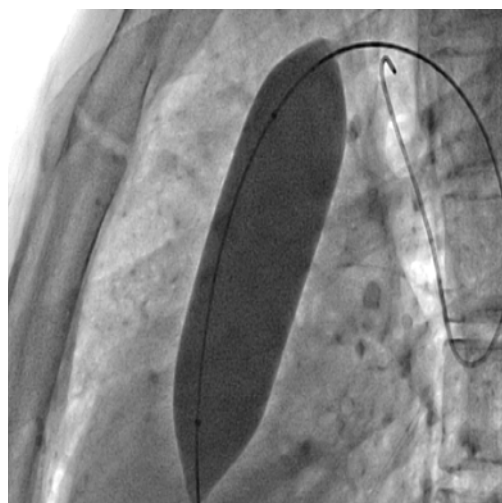
Between March 2004 and September 2012, balloon pulmonary valvuloplasty (BPV) was performed on 122 patients with congenital valvular PS (59 men and 63 women; age ranged from 14days to 50, mean 25 years) in Shahid Gangalal National Heart Centre. Doppler echocardiography was performed routinely before BPV to evaluate structure heart diseases. Clinically, all patients were symptomatic with mean NYHA II.

## Tecnique of pulmonary balloon valvuloplasty

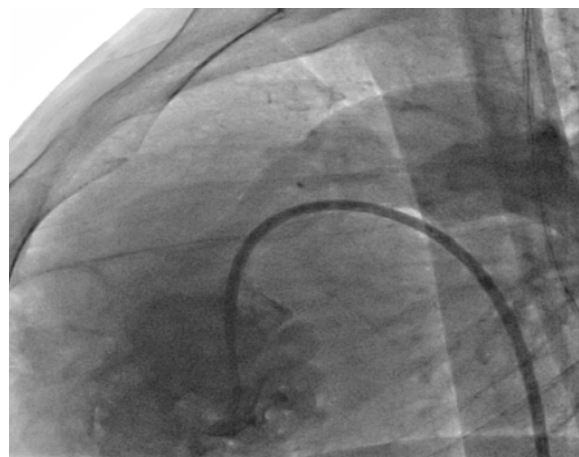
Vascular access via femoral vein, right ventricular (RV) angiography was done with a Berman balloon catheter

initially. Hemodynamic data including RV pressure and pulmonary artery (PA) pressure were documented during catheterization with Swan-Ganz catheter. BPV was performed basically according to the method of Kan et al<sup>5</sup> and Al Kasab et al<sup>6</sup> briefly; a long J tipped exchange guide wire (260 cm) was used to advance the balloon to the pulmonary valve site. Single-balloon technique was performed via femoral vein, with the balloon sized about 25% greater the annulus diameter. Usually, repeated balloon dilatation 2-3 times was performed and each inflation-deflation time was no more than 30 seconds.

**Fig1: Successful dilatation was indicated by the disappearance of the waist around the balloon under cineangiography.**



**Fig2: Post-stenotic dilatation of the main PA and rapid jet across the stenotic valve.**



All measured hemodynamic values were expressed as mean  $\pm$  SD (standard deviation). Paired Student's t test was used to compare data differences and p value  $<0.05$  was considered to be significant.

## Results

All patients had post-stenotic dilatation of the main PA and marked trabeculation of RV on right ventricular angiography. After balloon dilatation, the hemodynamic data were checked. After BPV, Right ventricle systolic pressure and pulmonary valve peak-to-peak systolic pressure gradient decreased from  $128 \pm 44.9$  to  $60 \pm 24.9$  mmHg ( $p < 0.001$ ) and  $89 \pm 38.6$  to  $45 \pm 22.4$  mmHg ( $p < 0.001$ ), respectively. There was no major complication, such as severe pulmonary regurgitation (PR) or death. One patient required emergent surgical management for tamponade due to laceration of main pulmonary artery. All patients were discharged the day after the procedure.

## Discussion

Our results demonstrate that BPV is a safe and effective procedure in treating patients with congenital valvular PS. BPV has become the choice of treatment for valvular PS since the first series reported by Kan et al<sup>5</sup> in 1982, and has almost replaced surgical valvotomy in pediatric patients. Most authors suggested that balloon to annulus ratio should not exceed 30% due to the higher risk of severe PR or annular laceration. In most cases we used the balloon sized about 25% greater the annulus diameter. In our study, the results were: 53.12% reduction of RV pressure and 51% reduction

of transvalvular pressure gradient on average which is slight lower to those of other centers (60% and 63%). Significant infundibular PS is a problem which may cause high residual pressure gradient after BPV. It was suggested by experts that myomectomy should be performed if immediate post-procedure RV pressure still exceeds 100 mmHg or pressure gradient more than 80 mmHg. We have a ten patients who had high pressure gradient even after a repeat BPV were undergone surgical valvotomy. Cases of infundibular spasm "suicidal Right ventricle" after BPV were reported by Al-Kasab et al.<sup>6</sup> However, among our patients, we did not find such conditions occurring. In addition, RV infundibular hypertrophy secondary to PS usually regresses gradually after the Procedure of BPV, which may be accelerated by the administration of oral beta-blockers. We prescribed Propranolol routinely to all patients after BPV with infundibular hypertrophy secondary to PS.

## Conclusion

BPV is a safe, effective and reliable treatment for patients with congenital valvular PS. The pulmonary balloon valvuloplasty is the treatment of choice for patients with symptomatic pulmonary stenosis and the single balloon is the traditional technique.

## Reference

- Guthrie GJ. On the anatomy and diseases of the neck of the bladder and the urethra. London: Burgess & Hill;1834.
- Semb BKH, Tijnonland S, Stake G. Balloon Valvotomy of congenital pulmonary valve stenosis with tricuspid valve insufficiency. *Cardiovasc Intervent Radiol* 1979;2:239-41.
- Pepine CJ et al. Percutaneous Balloon Valvuloplasty for Pulmonic Valve Stenosis in the Adult. *Am J Cardiol* 1982;50:1442-5.
- Kan JS, White RI, Jr, Mitchell SE, et al. Percutaneous balloon valvuloplasty: A new method for treating congenital pulmonary-valve stenosis. *N Engl J Med* 1982;307(9):540-2.
- Al Kasab S, Ribeiro PA, Al Zaibag M, et al. Percutaneous double balloon pulmonary valvotomy in adults: One- to two-year follow-up. *Am J Cardiol* 1988;62(10Pt1):822-4.
- Ali Khan MA, Yousef SA, Mullins CE. Percutaneous transluminal balloon pulmonary valvuloplasty for the relief of pulmonary valve stenosis with special reference to double-balloon technique. *Am Heart J* 1986;112(1):158-66.
- Lau KW, Hung JS, Wu JJ, et al. Pulmonary valvuloplasty in adults using the Inoue balloon catheter. *Cathet Cardiovasc Diagn* 1993;29(2):99-104.
- Bahl VK, Chandra S, Wasir HS. Pulmonary valvuloplasty using Inoue balloon catheter. *Int J Cardiol* 1994; 45(2):141-3.
- Bonow RO, Carabello B, Charles RM, et al. ACC/AHA guidelines for the management of patients with valvular heart disease. *J Am Coll Cardiol* 1998;32:1486-588.
- Donald's baim. Grossman's cardiac catheterization, angiography and intervention. 7<sup>th</sup> edition. 2006.
- Morton JK. Interventional cardiac catheterization handbook. 2<sup>nd</sup> edition. 2003.