



## Case Report

# Case reports of two unusual breast lumps

Pudasaini S<sup>1</sup>

<sup>1</sup>Department of Pathology, Nepal Medical College Teaching hospital, Jorpati, Kathmandu, Nepal

### Keywords:

Breast lump;  
Cysticercosis;  
Fine needle aspiration  
cytology;  
Histopathology;  
Myxoma

### ABSTRACT

Breast lump is a common diagnostic problem both to the general practitioner and to the surgeons. Cases like mammary myxoma and cysticercosis are rare findings and their diagnosis needs to be confirmed on histopathology. Myxoma of the breast is extremely rare and presents with painless swelling. Cysticercosis can affect any organ or tissue of the body and involvement of the breast is unusual. We present reports on two unusual breast lumps in young females with mammary myxoma and cysticercosis. The clinical presentation and its histopathological diagnosis is discussed.

## INTRODUCTION

Breast is an extremely rare location of myxoma. It is a tumor of mesenchymal origin. To date only few cases have been reported. Patient presents with slow growing painless mass. Microscopically it shows hypocellular vascular lesion with small bland spindle or stellate shaped tumor cells with small hyperchromatic nuclei and inconspicuous cytoplasm.<sup>1</sup>

Cysticercosis is a parasitic infection caused by *Cysticercus cellulosae* which is the larval stage of the pork tapeworm. It is commonly seen in developing countries. Common sites of infestation are skeletal muscles, subcutaneous tissue, breast, brain and eye.

Involvement of breast by cysticercosis is a rare presentation. Only few cases are reported in the literature. It is basically diagnosed on histopathology which shows diagnostic scolices within protruding mural nodules.<sup>2-4</sup> Literature search was carried out using keywords like mammary myxoma and cysticercosis. Here we present two unusual breast lumps- mammary myxoma and cysticercosis.

## CASE REPORT

### Case #1:

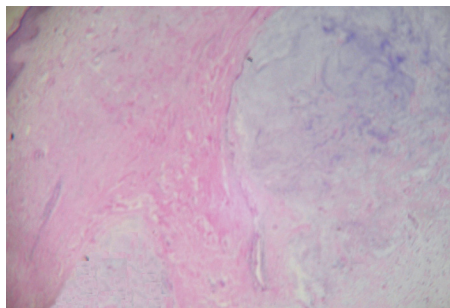
A thirty year-old female presented with painless swelling in the right breast for last ten years. It was gradually increasing in size. The patient was not lactating and she had no other complaints. On clinical examination the lump was raised from the skin surface and non tender. There was no change in the skin color and discharge. Bilateral axillary lymph nodes were not palpable. The clinical diagnosis was given as papilloma. Fine needle aspiration cytology (FNAC) was advised. FNAC was performed but diagnosis was not possible due to scanty aspirate. Excision of the lump was carried out and sent for histopathological examination. Specimen was skin covered nodular tissue measuring 4x3 cm with multiple cystic spaces on cut section. Histopathology revealed mass composed of vascular mucinous matrix (fig.1) with a network of fine collagen and tissue containing stellate and spindle shaped undifferentiated mesenchymal cells. Thus, it was diagnosed as mammary myxoma. On follow up, patient had no complaints and the wound was healing. She was asked to contact the hospital if there is any change or reappearance of lump in the breast. But the patient did not come to the hospital for the following 4 years.

### Correspondence:

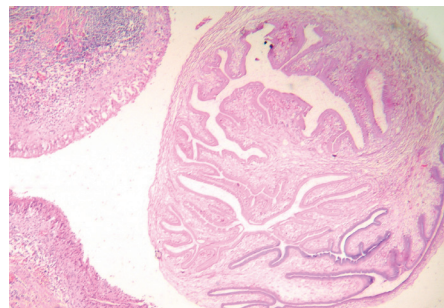
Dr. Sujata Pudasaini, MD

Assistant Professor, Department of Pathology, Nepal Medical College Teaching hospital, Jorpati, Kathmandu, Nepal

Email: sujatap2000@yahoo.com



**Figure 1:** Histopathology- Mammary myxoma showing mucinous matrix with collagen fibres. (HE Stain, X200).



**Figure 2:** Histopathology of breast cysticercosis showing cysticercosis with three layers. (HE Stain, X200).

### Case #2:

A 22 years-old female presented with small non tender lump of size 1x1 cm in the right breast for 8 months. The lump was soft to firm in consistency. The lump was not increasing in size. On examination of the bilateral breast there was no change in the skin, no nipple discharge and no other lumps identified. Bilateral axillary lymph nodes were not palpable. The clinical diagnosis was fibroadenoma. FNAC aspirate showed only few ductal cells. The lump was excised which showed cystic nodular swelling measuring 0.75 cm. Cut section showed serous fluid with white mass about 0.1 cm.

Section showed cystic wall lining of the cysticercosis with three layers namely corrugated cuticular layer with hair like protrusion (microtrichia), a thin middle cellular layer and a thick inner layer containing loosely packed network of small canaliculi. Inflammatory infiltrates, multinucleated giant cells and foreign body granulomas were seen in the wall of the cyst. These findings confirmed the diagnosis of cysticercosis.

Since the lump had been already excised and it was a case of extraneural cysticercosis, no other treatment modality was given to this patient. Regular follow up of the patient was done monthly for four months. There was no recurrence or complication during the follow up.

### DISCUSSION

Mammary myxoma is a rare condition presenting as breast lump. As shown by Paul Peter Rosen, only five cases have been reported till now,<sup>5</sup> which can be seen in both young and old female. Arihiro K et al in Japan found mammary myxoma in nineteen year old girl of three years duration. Tumour was multinodular measuring 5 x 4.5 cm and was diagnosed on histopathology.<sup>6</sup>

Mammary myxoma usually presents as subareolar swelling of more than one year duration with size of more than 5 cm.<sup>5,6</sup> Diagnosis is made on the basis of mucinous matrix with a network of fine collagen and fibroblasts. Chondroid

and lipoblastic differentiation will be absent. The myxoid material will be positive with alcian blue not staining the neoplastic cells. Few tumor cells are weakly immuno reactive for S-100 and  $\alpha$ -1 antichymotrypsin but not reactive for  $\alpha$ 1-antitrypsin, vimentin, epithelial membrane antigen, cytokeratin or estrogen receptor and progesterone receptor. Electron microscopy of the cells reveals abundant dilated rough endoplasmic reticulum, scant secondary lysosomes and no junctional complexes or basal lamina.

These tumors are benign lesion but in one case local recurrence and progression to high grade sarcoma with features of malignant fibrous histiocytoma were observed.<sup>7</sup> In another case of mammary myxoma, there were multiple recurrences. On its fourth recurrence it was myxosarcoma and on its fifth recurrence it was liposarcoma.<sup>7</sup>

The differential diagnosis of mammary myxoma includes myxoid neurofibroma, myxoid sarcoma, myxoid fibroadenoma and myxoid stromal change (myxomatosis). Presence of epithelial elements and multiple myxoid nodules distinguishes myxoid fibroadenoma and myxomatosis from myxoma. Strong immunoreactivity for S-100 identifies myxoid neurofibromas.<sup>5</sup>

Cysticercosis presenting as breast lump is rare.<sup>8</sup> FNAC diagnosis is possible if the right place is hit. In a case reported by Vuong PN et al, cysticercosis was diagnosed on FNAC which showed many inflammatory cells mixed with spiked spherules.<sup>9</sup> Few other studies showed that breast cysticercosis is common in Nepal and cysticercosis was diagnosed in cases which were clinically diagnosed as fibroadenoma.<sup>2,3</sup> Similarly Amatya BM et al showed that 8% of the cysticercosis was seen in the breast.<sup>4</sup> In expert hands cysticercosis can be diagnosed on FNAC alone and this was shown by Vuong PN et al in France.<sup>8</sup>

### CONCLUSION

Whenever patient presents with painless breast lumps of varying duration mammary myxoma and cysticercosis should be considered as differential diagnosis.

**REFERENCES**

1. Fletcher DM. Diagnostic Histopathology of tumors, Tumors of the breast. 1st edn. Churchill livingstone;1995. pp 635.
2. Geetha TV, Krishnanand BR, Pai CG. Cysticercosis of breast: A rare presentation. J Nep Med Assoc 2000;39:184-5.
3. Sah S, Jha PC, Gupta AK. An incidental case of breast cysticercosis associated with fibroadenoma. Indian J Pathol Microbiol 2001;44:59-61.
4. Amatya BM, Kimula Y. Cysticercosis in Nepal: a histopathological study of sixty two cases. Am J Surg Pathol 1999;23:1276-9.
5. Rosen PP, Rosen's Breast Pathology. 2nd edition. Lippincott Williams & Wilkins; 2001. pp869-70.
6. Arihiro K, Inai K, Kurihara K. Myxoma of the breast: report of a case with unique histopathological and immunohistochemical appearances. Acta Pathol Jpn 1993;43:340-6.
7. Rudan I, Rudan N. Locally recurring primary myxoma of the breast: An evidence of malignant alteration. Acta Med Croat 1996;50:209-11.
8. Marques CD, Kashimoto E. Cysticercosis of the breast: An uncommon cause of lumps. The breast journal 2006;12:179.
9. Vuong PN. Fine needle aspiration cytology of subcutaneous cysticercosis of the breast. Case report and pathogenic discussion. Acta Cytol 1989;33:659-62.