

A Study of FNAC of Cervical Lymph Nodes

Shakya G,¹ Malla S,¹ Shakya KN,² Shrestha R³

¹National Public Health Laboratory, Teku, Kathmandu, ²Department of Pediatrics, ³Department of Medicine, Kathmandu Medical College, Sinamangal, Kathmandu, Nepal

ABSTRACT

Background: Fine Needle Aspiration Cytology (FNAC) is a reliable and least expensive method suitable for developing countries like Nepal for the investigation of lymphadenopathy. Knowledge about the pattern of lymphadenopathy is useful in pathological reporting as well as in many clinical settings with diagnostic dilemma. This is a baseline study to investigate the pattern of cervical lymphadenopathy by lymph node FNAC in Nepalese population.

Methods: A retrospective study was conducted by critically analyzing the case reports on cervical lymph node FNAC from three years' records (July 2005 to June 2008) at the National Public Health Laboratory, Teku, Kathmandu. Review of all cytological reports were done according to standard guidelines and the diagnosis was classified and correlated with patients' age and ethnicity to explore the pattern and association.

Results: Of 508 cervical lymph node FNAC cases, 50.4% was reactive non-specific, 22.4% was tubercular, 4.8% malignant, 10% chronic granulomatous and the remaining was acute suppurative (12.4%). Highest incidence of malignancy was seen in the fifth decade (50%). Whereas, tubercular lymphadenopathy was found with increasing frequency through childhood (10.5%) and adolescence (21.7%) to young adulthood (30.4%), probably indicative of waning immunity of BCG vaccination. Ethnic groups comprising of Tamang, Sherpa and Bhote had the highest incidence of malignant as well as tubercular lymphadenopathy.

Conclusion: The relationship of malignant and tubercular lymphadenopathy with age and ethnicity deserves further study. Efforts at preventing tubercular and early diagnosing malignant lymphadenopathy and reducing morbidity in general will find great usefulness in such associations.

Key words: Cervical Lymphadenopathy, Fine Needle Aspiration Cytology, Pattern

INTRODUCTION

Enlargement of cervical lymph nodes is a common and worrying presentation in adults as well as in children. This may be caused by a benign condition like reactive hyperplasia but a lymphoma or a metastatic malignancy may also be responsible.¹ A Tubercular lymphadenitis is another important differential diagnosis in the developing

countries.² Fine Needle Aspiration Cytology (FNAC) of the lymph nodes is a simple and rapid diagnostic procedure which can decide the nature of the lymphadenopathy.³ Its sensitivity and specificity have been documented by several studies in the past.⁴⁻⁶ Use of aspiration cytology is accepted as a primary method of diagnosis in reactive, infective and metastatic lymphadenopathy⁷ and in combination with immunological evaluation has distinctly

Correspondence: Dr. Geeta Shakya, National Public Health Laboratory, Teku, Kathmandu, Fax: 01-252375, Email: nphl@wlink.com.np

improved diagnostic accuracy in cases of lymphoma.^{8,9} But, predominantly, cytomorphology alone decides the nature of lymphadenopathy. In the clinical management of patients with enlarged lymph nodes various factors like age, ethnicity, presence of known infection and the previous medical history are taken into consideration. Knowledge about the pattern of lymphadenopathy in a population facilitates pathological reporting and helps the clinician in making focused investigation and planning the treatment course. So, the present study was done to investigate the pattern of cervical lymphadenopathy among Nepalese population.

METHODS

This is a retrospective study carried out at the National Public Health Laboratory (Cytopathology section), Teku, Kathmandu, Nepal. From the records of three years (July 2005 to June 2008), all cervical lymph node FNAC case reports were included in the study. They were reviewed for age, ethnicity, cytomorphology and diagnosis. Cases in which diagnosis was equivocal or patient particulars were inadequate were excluded from the study. The ages were arranged into decades of age groups. The ethnicity was categorized into five major ethnic groups of Nepal for the purpose of this study. Cases with a single cytological diagnosis were classified as described by Datta BN.¹⁰ Tabulation of diagnosis was done to correlate with age groups and ethnicity. Cytomorphological features in each report were reviewed for classifying the diagnosis. Cytomorphological features of epithelioid and Langhan's giant cells with caseation necrosis were reported as Tubercular lymphadenitis. Chronic granulomatous lymphadenitis was grouped with the cytological features of epithelioid cells, lymphocytes and Langhan's giant cells without caseous material. Features of necrotic cellular debris mainly, with scattered polymorphonuclear leucocytes was grouped under suppurative lymphadenitis. Hodgkin's disease with Reed-Sternberg cells was classified separately. Metastatic malignancy was subdivided according to distinct cytological features into Adenocarcinoma and Squamous cell carcinoma. Standard guidelines for cytological diagnosis⁸ were followed as far as practicable. The results were analyzed using appropriate statistical tools.

RESULTS

Total number of patients included in the study was 508, who had undergone FNAC for enlarged cervical lymph nodes. Their demographic profile is given in Table 1. There was slight male preponderance with the mean age in the middle of the third decade. The ethnicity of patients is shown on Figure 1. Maximum number of patients was in ethnic group B which comprised of

Bahum and Chhetri. Group R comprising of Rai, Limbu, Gurung and Magar had the least number of patients. The pattern of cervical lymphadenopathy is shown in Table 2. Half of the lymphadenopathy (50.4%) was reactive non-specific with unknown cause. This was followed in frequency by tubercular (22.4%) and acute suppurative (12.4%). Chronic granulomatous type constituted 10% of cases. Malignancy was diagnosed in 24(4.8%) cases. Of those, metastatic cases (14, 2.8%) slightly outnumbered the lymphomas (10, 2%). There were only 2(0.4%) cases of Hodgkin's lymphoma diagnosed in the series. Both were in the third decade age group. The comparison between inflammatory and malignant lymphadenopathy in various age groups is shown in Figure 2 and similar comparison according to ethnicity is given in Figure 3. Highest incidence of malignancy was seen in 51-60 year age group and no case was seen in the second and after the sixth decade. Ethnic group T, comprising of Tamang, Sherpa and Bhote had the highest incidence of malignancy (6/67, 9%), whereas, the lowest frequency was in ethnic group N, comprising of Newar (2/112, 1.6%). Tubercular lymphadenitis was most commonly observed in young adults of 21-30 year age group (52/171, 30.4%) but no case was seen beyond the sixth decade (Figure 4). Ethnic group T, comprising of Tamang, Sherpa and Bhote had the highest incidence and ethnic group R, consisting of Rai, Limbu, Gurung and Magar had the lowest incidence of tubercular lymphadenitis (Figure 5).

There were 23 cases not included in the study, of whom, 17 cases had inadequate aspiration material and in six cases the cytological diagnosis was equivocal. Repeat FNAC was advised when material was insufficient for cytological details but biopsy for histopathology was suggested in equivocal cases.

Table 1. Demographic profile of patients undergoing FNAC of cervical lymph nodes

Particulars	Number	(%)
Male	261	51.4
Female	247	48.6
Age range 20 months - 81 years		
Mean age 25.7 years		
	<10	57 11.2
	11-20	120 23.62
	21-30	171 33.66
Age group (in years)	31-40	110 21.65
	41-50	24 4.73
	51-60	16 3.15
	> 60	10 1.97

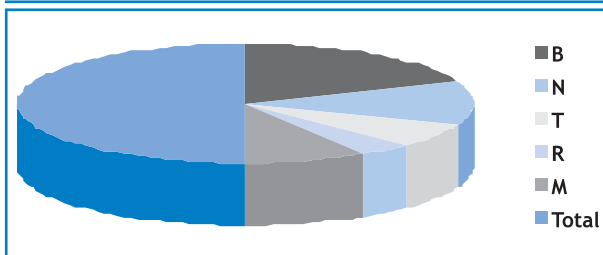


Figure 1. Ethnicity of patients

Percentage of ethnic groups:

- B (Bahun and Chhetri) : 91/508 = 37.6%
- N (Newar) : 122/508 = 24%
- T (Tamang, Sherpa and Bhote) : 67/508 = 13.2%
- R (Rai, Limbhu, Gurung and Magar) : 41/508 = 8.1%
- M (Madhesi, Muslim and Tharu) : 87/508 = 17.1%

Table 2. Pattern of Lymphadenopathy on FNAC of cervical lymph nodes (n = 508)

Cytological diagnosis	Number	%
Reactive non-specific	256	50.4
Acute suppurative	63	12.4
Chronic granulomatous	51	10
Tubercular	114	22.4
Non Hodgkin's Lymphoma	8	1.6
Hodgkin's Lymphoma	2	0.4
Metastatic carcinoma (Adenocarcinoma, 1.6% & Squamous cell carcinoma, 1.2%)	14	2.8
Total	508	100

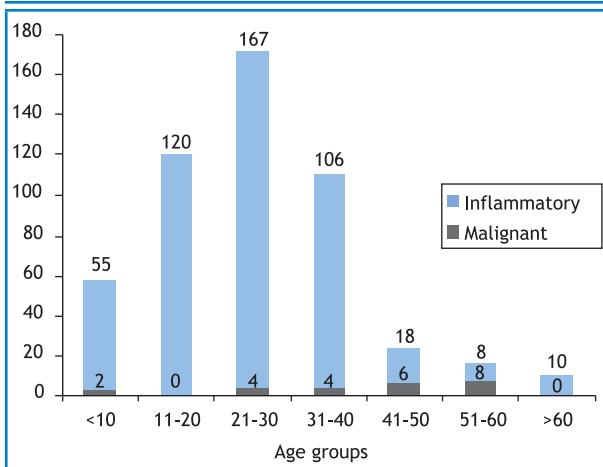


Figure 2. Comparison between inflammatory and malignant lymph nodes in patients of various age groups undergoing FNAC of cervical lymph nodes (n=508)

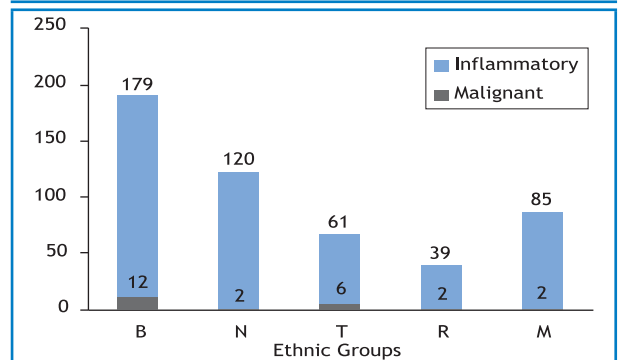


Figure 3. Comparison between inflammatory and malignant lymph nodes in patients of various ethnic groups undergoing FNAC of cervical lymph nodes (n= 508)

B (Bahun and Chhetri), N (Newar), T (Tamang, Sherpa and Bhote), R (Rai, Limbhu, Gurung and Magar), M ((Madhesi, Mushlim and Tharu).

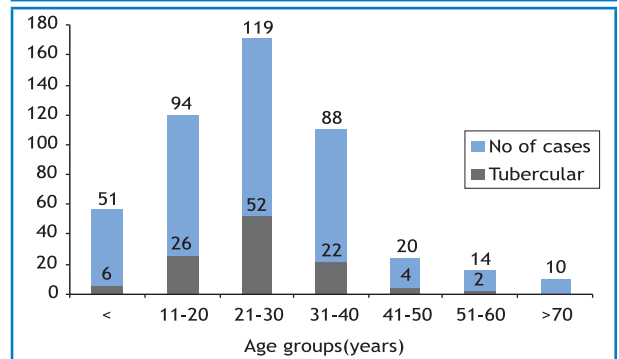


Figure 4. Comparison between inflammatory and malignant lymph nodes in patients of various age groups undergoing FNAC of cervical lymph nodes (n=508)

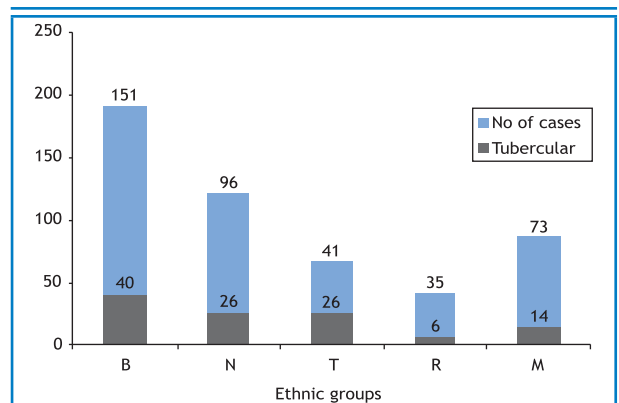


Figure 5. Relationship between ethnic group and tubercular lymphadenitis in patients undergoing FNAC of cervical lymph nodes (n=508)

B (Bahun and Chhetri), N (Newar), T (Tamang, Sherpa and Bhote), R (Rai, Limbhu, Gurung and Magar), M ((Madhesi, Mushlim and Tharu)

DISCUSSION

Cytology of lymph nodes has become a window for diagnosis of many diseases. Optimal material and experience, when combined, make cytological diagnosis of equal significance as histopathology.¹¹ In many clinical settings it is very difficult to decide which patient is more likely to have a reactive or neoplastic lymphadenopathy. Here, knowledge about the pattern of lymphadenopathy is helpful to the clinician for solving the dilemma. In the present series, half the cases (50.4%) were reactive non-specific. This is because in the cervical region most cases may be of acute lymphadenitis, due to infections of the oral cavity, nose and ears. Acute suppurative (12.4%) and chronic granulomatous (10%) were other cytological patterns of reactive lymphadenopathy. Tuberculosis (22.4%) was another important differential diagnostic pattern. FNAC was reported to have 77% sensitivity in the detection of tubercular lymphadenopathy.¹² Sensitivity, specificity and diagnostic accuracy was reported to be 97%, 97.5% and 97.4% respectively in yet another study in which, cytomorphological features of epithelioid and giant cells with caseation necrosis was associated with higher percentage of AFB positivity.¹³ Early diagnosis is particularly important in tubercular lymphadenopathy due to its curability. Lymphoma was seen in 2% cases. But, due to reported wide variability in accuracy of cytological diagnosis of lymphoma, FNA Cytology is more readily accepted for evaluation of patients with suspected recurrent lymphoma, or deep seated primary lymphomas.⁷ Metastatic carcinoma was found in 2.8% cases. In another large study, nasopharyngeal carcinoma was reported as most frequent primary site in cervical metastatic lymphadenopathy.⁶

On correlating pattern of lymphadenopathy with age groups, it revealed that half the cases (8/16=50%) belonged to malignant lymphadenopathy in the fifth decade. This may be because adult or elderly patients often react to infections with only slight to modest lymph node enlargement.⁷ Therefore, distinct lymphadenopathy in an elderly patient will arouse suspicion of malignancy and justify immediate needle biopsy. Highest frequency of malignancy was found in ethnic group T, comprising of Tamang, Sherpa and Bhote. This elevation in frequency may be due to increased exposure to carcinogens as occupational hazards, food habits or cytogenetic susceptibility. Tubercular lymphadenopathy was found with increasing frequency through childhood (10.5%) and adolescence (21.7%) to young adulthood (30.4%) which may be due to waning immunity of BCG vaccination given soon as after birth. But the susceptibility of ethnic group T, comprising of Tamang, Sherpa and Bhote with a frequency of 38.8 % may be due to lack of immunization and prevalent low socio-economic conditions rather than genetic predisposition.

The present study was done in a central referral laboratory and so, all patients have the bias of case selection. Such a study would have been more appropriate with a community-based protocol. The ethnicity too, would be more heterogeneous in a rural population. Besides, this is a retrospective study and it lacks the invaluable case follow up details and prognostic results.

CONCLUSION

The present study has reported the pattern of cytological diagnosis on FNAC of enlarged cervical lymph nodes among Nepalese population. We have reported the association of malignant and tubercular lymphadenopathy with age and ethnicity. We believe this information would be useful in many clinical settings with diagnostic dilemma. This will facilitate pathological reporting and focused clinical investigation under the current Nepalese perspective. This study also highlights the usefulness of FNAC as a reliable method of investigation for lymphadenopathy.

REFERENCES

1. Koojan G. Lymph nodes and thymus. Atlas of Diagnostic Cytopathology. 2nd ed. New York: Churchill Livingstone; 1988. p. 225-35.
2. Pamra SR, Baily GVS, Gupta SP. Cervical Lymphadenopathies. *Ind J Tub* 1987;18:96-100.
3. Sharma R, Amanjit. Diagnostic Cytopathology. In: Mohan H. ed. Textbook of Pathology 5th ed. New Delhi: Jaypee Brothers; 2005. p. 922-40.
4. Shas A, Webber C, Marti J. Fine needle aspiration in the diagnosis of cervical lymphadenopathy. *Am J Surg* 1986;12(4):420-3.
5. Malakar D, Jajoo ILN, Swaruup K, Gupta OP, Jain AP, Poflee VW. A clinical evaluation of fine needle aspiration cytology in the diagnosis of lymphadenopathy. *Ind J Tub* 1991;38:17.
6. Hsu C, Leung BSY, Lau SK, Sham JST, Choy D, Engzell U. Efficacy of fine-needle aspiration and sampling of lymph nodes in 1,484 chinese patients. *Diagn Cytopathol*. 2006;6(3):154-9.
7. Skoog L, Tani E. Lymphnodes. In: Gray W, Mckee GT, ed. Diagnostic Cytopathology 2nd ed. New York: Churchill Livingstone; 2003. p. 501-36.
8. Oertel J, Oertel B, Kastner M. The value of immunocytochemical staining of lymph node aspirates in diagnostic cytology. *Br J Haematol* 1988;70:307-16.
9. Ravinsky E, Morales C, Kutryk E, Chrobak A, Paraskevas T. Cytodiagnosis of lymphoid proliferations by fine needle aspiration on biopsy: Adjunctive value of flow cytometry. *Acta Cytol* 1999;43(6):1070-78.
10. Datta BN. Pathology of Lymphoid Tissue Including Spleen and Thymus. Textbook of Pathology 2nd ed. New Delhi: Jaypee Brothers; 2004. p. 860-971.
11. Koss LG. Diagnostic Cytology and the Histopathological Basis. 4th ed. Philadelphia: Lippincott Company; 1994. p.194-8.

12. Lau SK, Wei WI, Hsu C, Engzell UCG. Efficacy of fine needle aspiration cytology in the diagnosis of tuberculous cervical lymphadenopathy. *The Journal of Laryngology and Otology*. 1990;104:24-9.
13. Ahmed SS, Akhtar S, Akhtar K, Naseem S, Manoor T. Study of Fine Needle Aspiration Cytology in Lymphadenopathy with special Reference to Acid-fast staining in cases of Tuberculosis: *J. K. Science* 2005;7(1):1-4.